



## PATIENT

Fluffy Movsesyan

## SPECIES

Canine

## BREED

Pomeranian

## SEX

MN

## AGE

8Y

## WEIGHT

5.3kg

## INTERPRETED BY

Sebastian Schaub, DVM  
Dr. med. vet.  
DipECVDI

## IMAGING PERFORMED BY

Dr. Sherry Vartanian

## HOSPITAL NAME

My Pet Mobile Vet

## REFERRING VET

Dr. Sherry Vartanian

## INVOICE

73837

## DATE

2-18-26

## PRESENTING CLINICAL SIGNS

O requests house call for P unable to use hind limbs. 6 months ago, O thought P didnt want to walk because he was "fat and lazy". 1 month ago, started having a lot of difficulty walking. Was on/off symptoms, but the last 4-5 days have been consistently not able to walk. Will kind of walk on grass, but legs will sway to one side.

## RADIOGRAPHIC STUDY OF THE LUMBAR SPINE AND PELVIS

Radiographs of the lumbar spine and pelvis in two image planes are provided of review.

## RADIOGRAPHIC FINDINGS

The osseous and surrounding soft tissue structures of the lumbar spine reveal no abnormalities. The intervertebral disc spaces along the lumbar spine have an even width.

Both coxofemoral joints present advanced osteophyte new bone formation and the femoral heads are deformed. The acetabular groove bilaterally is shallow and dorsal subluxation of the femoral heads is appreciated. The remainder of the osseous structures of the pelvis are within normal limits.

## RADIOGRAPHIC DIAGNOSIS

- Advanced osteoarthritis coxofemoral joints due to severe hip dysplasia and secondary dorsal subluxation of the femoral heads
- Normal lumbar spine

## INTERPRETATION OF THE FINDINGS & FURTHER RECOMMENDATIONS

The changes of the coxofemoral joints can contribute to the clinical signs. However, the findings present long standing disease, and the recent onset of clinical signs is increasing the odds for possible underlying neurological deficits.



## PATIENT

Fluffy Movsesyan

## SPECIES

Canine

## BREED

Pomeranian

## SEX

MN

## AGE

8Y

## WEIGHT

5.3kg

## INTERPRETED BY

Sebastian Schaub, DVM  
Dr. med. vet.  
DipECVDI

## IMAGING PERFORMED BY

Dr. Sherry Vartanian

## HOSPITAL NAME

My Pet Mobile Vet

## REFERRING VET

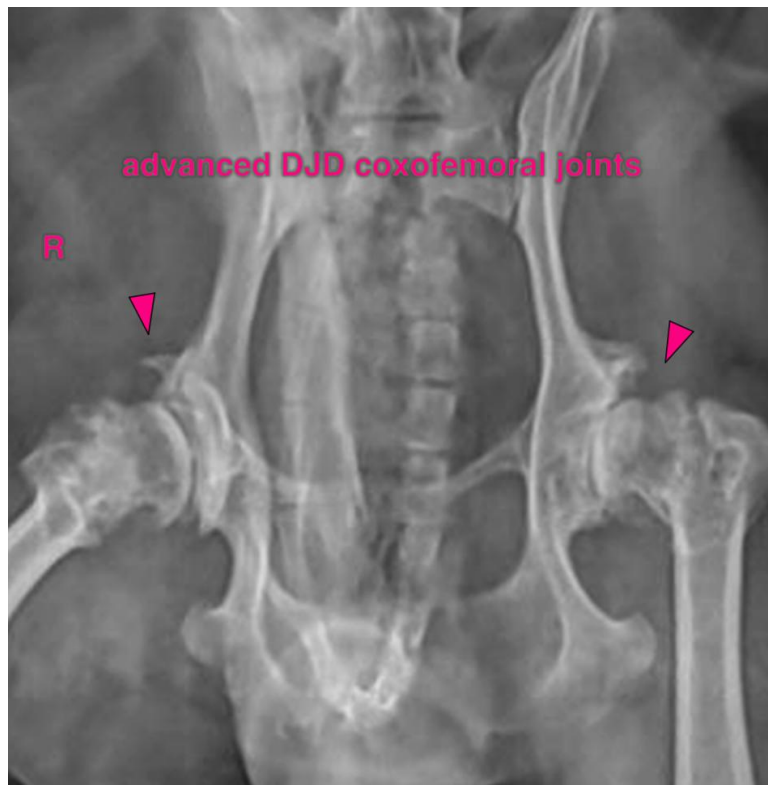
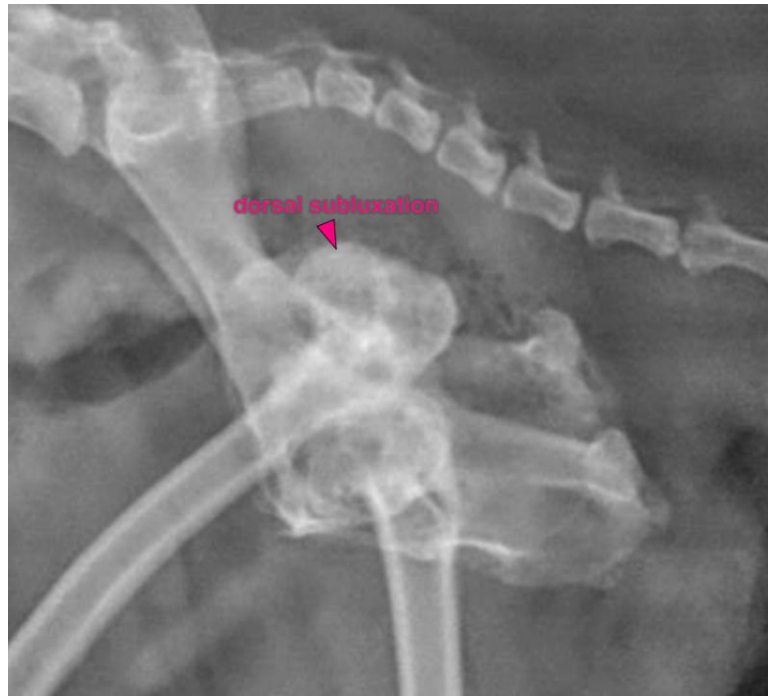
Dr. Sherry Vartanian

## INVOICE

73837

## DATE

2-18-26





Teleradiology

Educational Teleconsultation Services™

## PATIENT

Fluffy Movsesyan

## SPECIES

Canine

## BREED

Pomeranian

## SEX

MN

## AGE

8Y

## WEIGHT

5.3kg

## INTERPRETED BY

Sebastian Schaub, DVM  
Dr. med. vet.  
DipECVDI

## IMAGING PERFORMED BY

Dr. Sherry Vartanian

## HOSPITAL NAME

My Pet Mobile Vet

## REFERRING VET

Dr. Sherry Vartanian

## INVOICE

73837

## DATE

2-18-26

The information and recommendations provided are based on the images presented by the referring veterinarian/sonographer. No evaluation can be communicated regarding pathology that was not visible in the image/video clips provided.

Thank you for this referral. If the clinical or image interpretation does not parallel your findings or if I can be of any further assistance please contact me.

**Sebastian Schaub**, Sebastian Schaub, DVM, Dr. med. vet. DipECVDI  
[info@sonopath.com](mailto:info@sonopath.com)