



**PATIENT PRESENTING CLINICAL SIGNS**

**Nakittah Jones** P has been vomiting since the 16th, history of linear foreign body as a kitten, AFAST - concern for retroperitoneal mass.

**SPECIES** Abnormal PE/Chem/CBC/UA Results: EPOC: Bicarb 34.2, Ca 0.89, Cl 110, Crea 2.6, K 2.3, lac 4.46, pH 7.531, tco2 34.3, BE 11.6, BUN >120 Tense/painful abdomen - Feels as though there is a large mass effect in mid-abdomen. Patient is painful upon palpation. Approximately 7% dehydration, BCS 2/5 - P appears to have muscle wasting overall

**Feline**

**BREED** COMPUTED TOMOGRAPHY OF THE ABDOMEN

**DSH** A high resolution pre- and post-contrast CT study of the is provided for review.

**SEX** COMPUTED TOMOGRAPHIC FINDINGS

**Female** The serosal fat presents normal attenuation behavior. There is no evidence of peritoneal effusion or peritonitis.

**AGE** Both kidneys present within normal limits for size, shape and organ architecture. After contrast administration a bilaterally symmetric and uniform nephro- and pyelogram is noted.

**7** In the region of the left adrenal gland, a well-defined spherical, uniform soft tissue attenuating and heterogeneous contrast enhancing mass, measuring 3.0 cm in diameter is seen. The caudal vena cava level with the mass is deviated to the right.

**INTERPRETED BY** The right adrenal gland is normal in size and shape.

Sebastian Schaub, DVM  
Dr. med. vet. DipECVDI Both liver and spleen present with normal shape, even surface, uniformly attenuating parenchyma and homogeneous contrast enhancement, unremarkable.

**HOSPITAL NAME** The pancreas is evenly contoured, the pancreatic parenchyma is homogeneous and presents uniform contrast enhancement.

Wilvet Salem The ileum is mild to moderately dilated and contains linear, mild hyperattenuating, tap like material. The tap like material can also be appreciated in the transverse colon.

**REFERRING VET** The bony and surrounding soft tissue structures reveal no abnormalities.

Dr. Crystal Ebert, DVM COMPUTED TOMOGRAPHIC DIAGNOSIS

- Retroperitoneal soft tissue mass – likely originating from the left adrenal gland
- Foreign material in the ileum and the colon

**INVOICE** INTERPRETATION OF THE FINDINGS & FURTHER RECOMMENDATIONS

50405 The foreign material in the ileum is considered as the underlying pathology, responsible for the presenting clinical signs. Some of the tap-like material – possible plastic band – is already appreciated in the colon. The material in the ileum might be trapped in the ileum by the ileocolic junction. If clinical signs persist, surgical intervention is the therapy of choice.

**DATE** 2-18-22 The retroperitoneal mass is most consistent with left adrenal neoplasia – such as (non)functional



**PATIENT**

Nakittah Jones

adenocarcinoma. There is no evidence of vascular invasion and complete surgical resection appears feasible – adhesions with the caudal vena cava are possible.

**SPECIES**

Feline

**BREED**

DSH

**SEX**

Female

**AGE**

7

**INTERPRETED BY**

Sebastian Schaub, DVM  
Dr. med. vet. DipECVDI

**HOSPITAL NAME**

Wilvet Salem

**REFERRING VET**

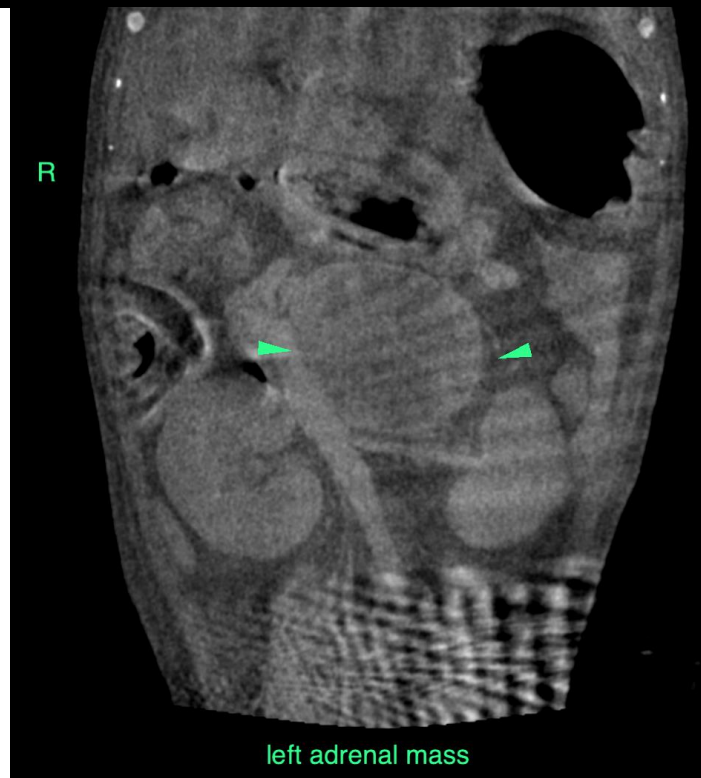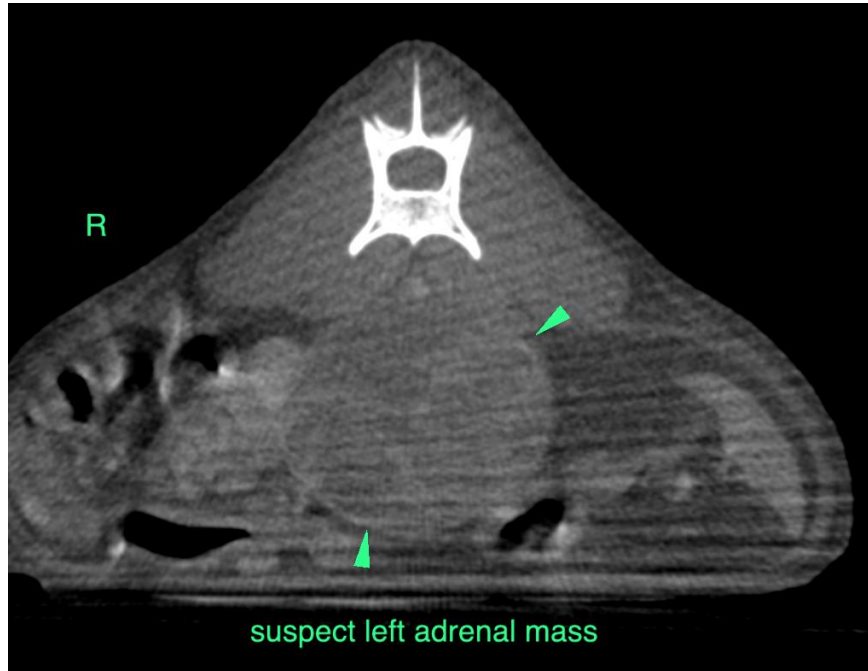
Dr. Crystal Ebert,  
DVM

**INVOICE**

50405

**DATE**

2-18-22





**PATIENT**

Nakittah Jones

**SPECIES**

Feline

**BREED**

DSH

**SEX**

Female

**AGE**

7

**INTERPRETED BY**

Sebastian Schaub, DVM  
Dr. med. vet. DipECVDI

**HOSPITAL NAME**

Wilvet Salem

**REFERRING VET**

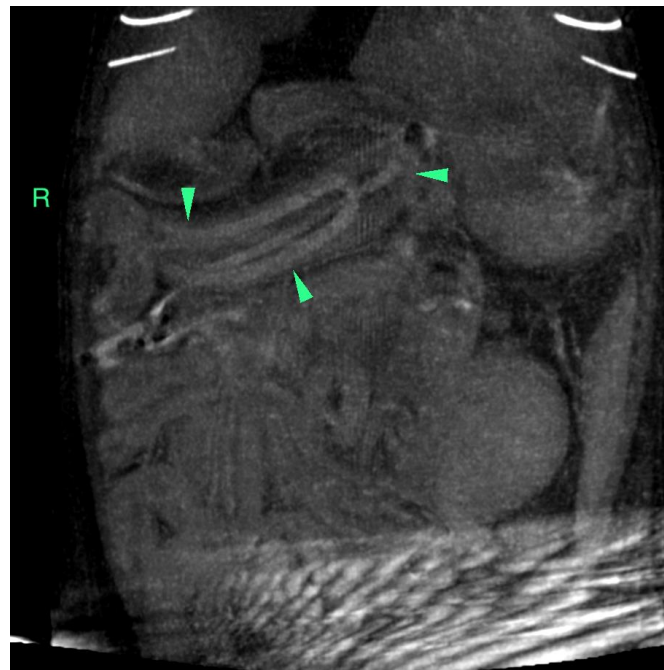Dr. Crystal Ebert,  
DVM

**INVOICE**

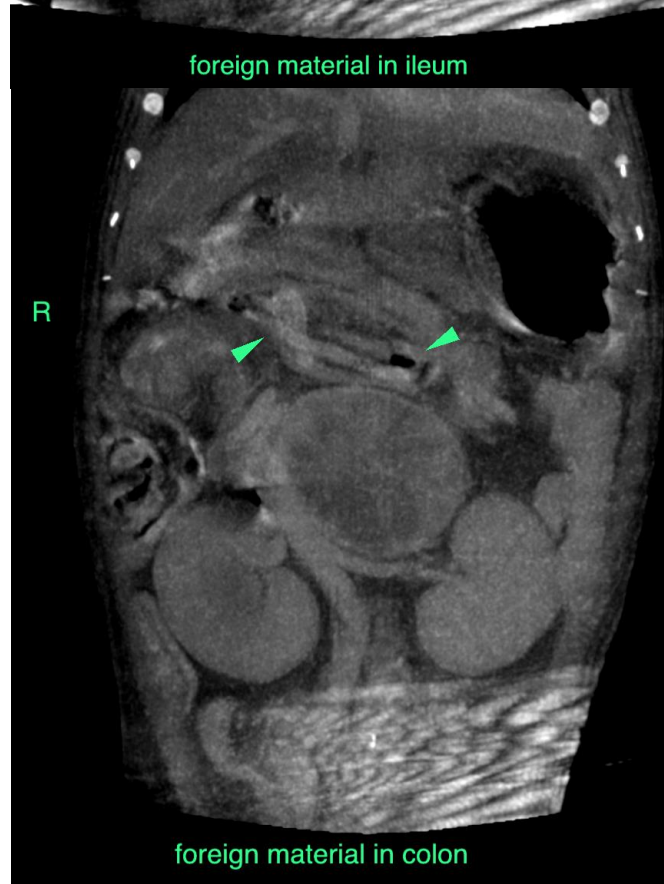
50405

**DATE**

2-18-22



foreign material in ileum



foreign material in colon



**PATIENT**

Nakittah Jones

The information and recommendations provided are based on the images presented by the referring veterinarian/sonographer. No evaluation can be communicated regarding pathology that was not visible in the image/video clips provided.

**SPECIES**

Feline

Thank you for this referral. If the clinical or image interpretation does not parallel your findings or if I can be of any further assistance please contact me.

**BREED**

DSH

**Sebastian Schaub**, Sebastian Schaub, DVM, Dr. med. vet. DipECVDI  
sebast.schaub@gmail.com

**SEX**

Female

**AGE**

7

**INTERPRETED BY**

Sebastian Schaub, DVM  
Dr. med. vet. DipECVDI

**HOSPITAL NAME**

Wilvet Salem

**REFERRING VET**

Dr. Crystal Ebert,  
DVM

**INVOICE**

50405

**DATE**

2-18-22