



PATIENT

L'il Missy Urias

PRESENTING CLINICAL SIGNS

L'il Missy, a 14 yo FS Pomeranian X, was presented for further evaluation of a large intrathoracic mass seen on previous radiographs. An intermittent cough is present, otherwise she is asymptomatic. Blood work revealed a neutrophilia, elevated liver enzymes (ALP>ALT), mild hyperbilirubinemia. Arrhythmia with long pauses noted - atropine responsive
 Abnormal PE/Chem/CBC/UA Results: Neutrophilia, elevated liver enzymes (ALP>ALT), mild hyperbilirubinemia. Arrhythmia with long pauses noted - atropine responsive.

SPECIES

Canine

BREED

Pomeranian X

COMPUTED TOMOGRAPHY OF THE THORAX AND ABDOMEN

A pre- and post-contrast CT study of the thorax and in a bone, lung and soft tissue reconstruction are provided for review.

COMPUTED TOMOGRAPHIC FINDINGS

SEX

FS

Thorax

The bony and surrounding soft tissue structures are within normal limits.

AGE

14

The sternal, cranial mediastinal and tracheobronchial lymph nodes are small elongated with a normal short-to-long-axis-ratio is < 0.5, the attenuation and contrast enhancement pattern is uniform and considered within normal limits.

INTERPRETED BY

Sebastian Schaub, DVM
 Dr. med. vet. DipECVDI

The cardiovascular structures including the pulmonary vasculature are within normal limits.

Likely originating from the right middle lung lobe, a large, well-defined, soft tissue attenuating and peripherally mild mineralizing mass, measuring 7.2 x 5.8 x 11.8 cm in size, is visible. Post contrast administration, the mass presents a heterogeneous contrast enhancement pattern. The heart is displaced to the left by the mass effect. The right cranial and caudal lung lobe are distorted and compressed by the mass effect.

HOSPITAL NAME

Animal Health Partners

Small incidental gas pockets are seen within the esophageal lumen, there is no evidence of abnormal dilation.

Abdomen

REFERRING VET

Dr. Ashley Gold

The serosal fat presents normal attenuation behavior. There is no evidence of peritoneal effusion or peritonitis.

INVOICE

50437

Both kidneys present within normal limits for size, shape and organ architecture. A moderate amount of mineral attenuating material is associated with the renal pelvis bilaterally. After contrast administration a bilaterally symmetric and uniform nephro- and pyelogram is noted.

The adrenal glands are within normal limits for size, shape and organ architecture.

DATE

2-18-22

The spleen presents with normal shape, even surface, uniformly attenuating parenchyma and homogeneous contrast enhancement, unremarkable.

In the hilar region of the left medial liver lobe, an ill-defined, heterogeneous contrast enhancing roundish intraparenchymal lesion, measuring approximately 1.9 cm in diameter is seen. In the



PATIENT

L'il Missy Urias

right lateral abdomen, a irregular, ovoid shaped, uniform soft tissue attenuating and heterogeneous contrast enhancing mass is seen, presenting a small connection with the caudate process of the caudate liver lobe. The respective hepatic vein is draining the mass. The right abdominal mass is measuring 6.5 x 5.1 x 8.2 cm in size.

SPECIES

Canine

The pancreas is evenly contoured, the pancreatic parenchyma is homogeneous and presents uniform contrast enhancement.

The position, delineation, wall and content of the gastrointestinal tract are considered within normal limits throughout.

BREED

Pomeranian X

Multifocal moderate spondylosis formation is seen along the lumbar spine.

COMPUTED TOMOGRAPHIC DIAGNOSIS

SEX

FS

- Large pulmonary mass, suspect origin in right medial lung lobe with dystrophic mineralization
- Pedunculated hepatic mass, originating from the caudate process of the caudate liver lobe
- Intraparenchymal nodule hilar region left medial liver lobe
- Nephrolithiasis without evidence of obstruction
- Spondylosis deformans

AGE

14

INTERPRETATION OF THE FINDINGS & FURTHER RECOMMENDATIONS

The findings are consistent with the history of a large right sided intrathoracic mass – due to the size, there is some uncertainty regarding the origin – I suspect origin in the right middle lung lobe with mass effect on the remaining lung lobes. Primary pulmonary neoplasia such as bronchogenic carcinoma is considered likely. FNA sampling of the mass can be performed for further definition. Complete surgical excision is considered feasible, but adhesions with the surrounding structures are possible.

INTERPRETED BY

Sebastian Schaub, DVM
Dr. med. vet. DipECVDI

HOSPITAL NAME

Animal Health
Partners

The abdominal mass is considered as a second entity with neoplastic transformation of the liver, such as hepatocellular adenoma/carcinoma with possible metastatic spread to the left medial liver lobe versus regeneration nodule/nodular hyperplasia. Complete surgical excision of the pedunculated mass is feasible, but not the intraparenchymal lesion in the left medial liver lobe – consider FNA sampling for further definition.

REFERRING VET

Dr. Ashley Gold

INVOICE

50437

DATE

2-18-22



PATIENT

L'il Missy Urias

SPECIES

Canine

BREED

Pomeranian X

SEX

FS

AGE

14

INTERPRETED BY

Sebastian Schaub, DVM
Dr. med. vet. DipECVDI

HOSPITAL NAME

Animal Health
Partners

REFERRING VET

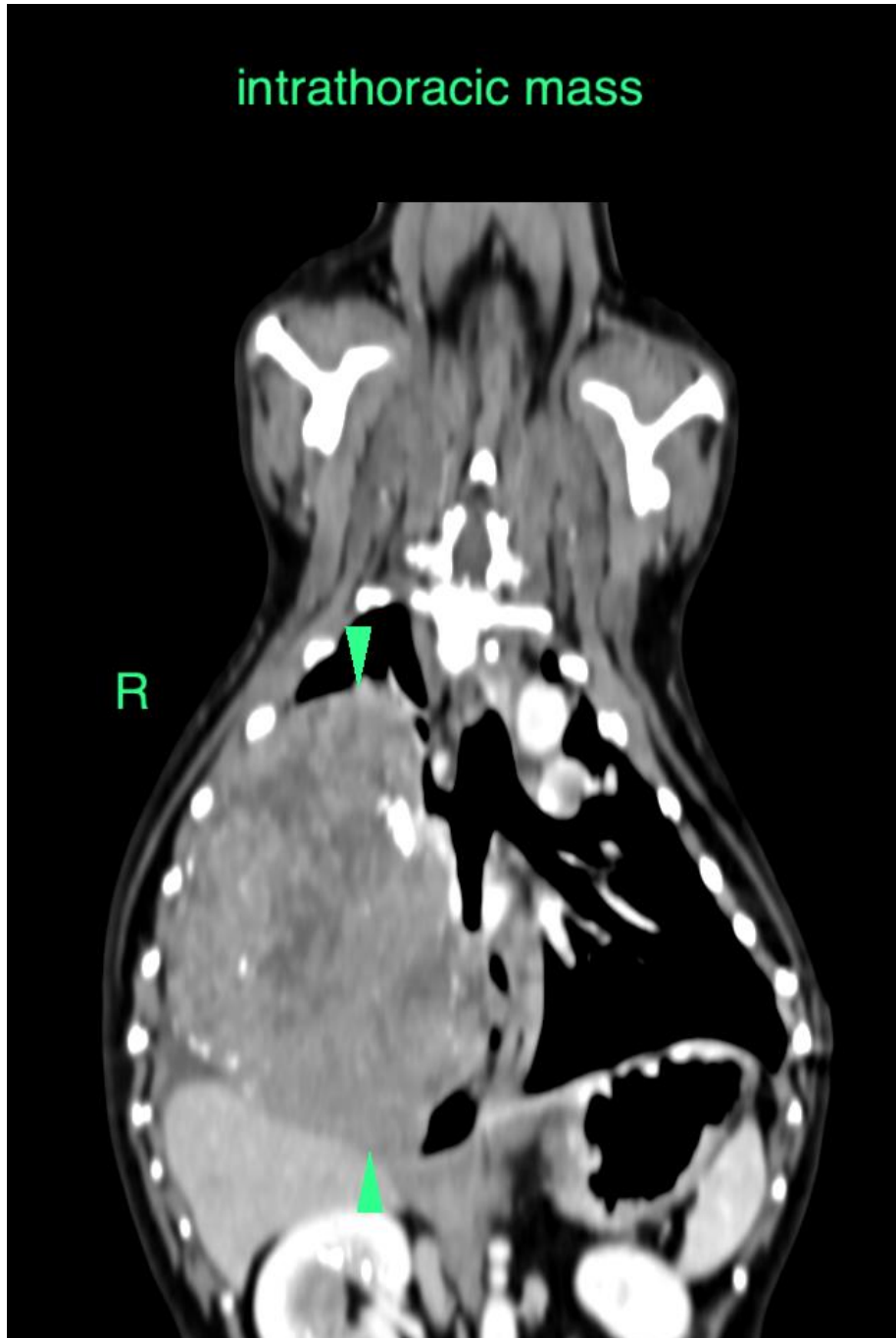Dr. Ashley Gold

INVOICE

50437

DATE

2-18-22





PATIENT

L'il Missy Urias

SPECIES

Canine

BREED

Pomeranian X

SEX

FS

AGE

14

INTERPRETED BY

Sebastian Schaub, DVM
Dr. med. vet. DipECVDI

HOSPITAL NAME

Animal Health
Partners

REFERRING VET

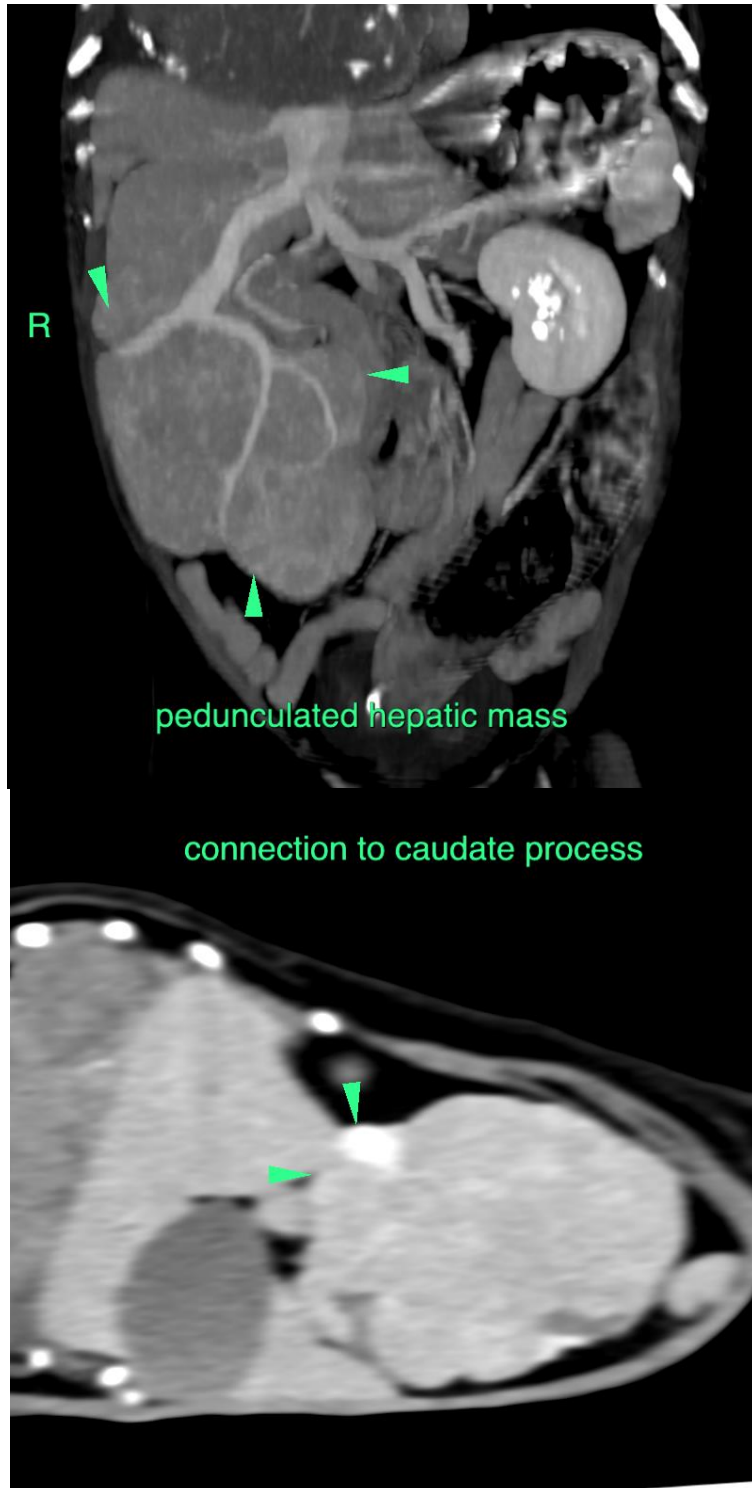
Dr. Ashley Gold

INVOICE

50437

DATE

2-18-22





PATIENT

L'il Missy Urias

SPECIES

Canine

BREED

Pomeranian X

SEX

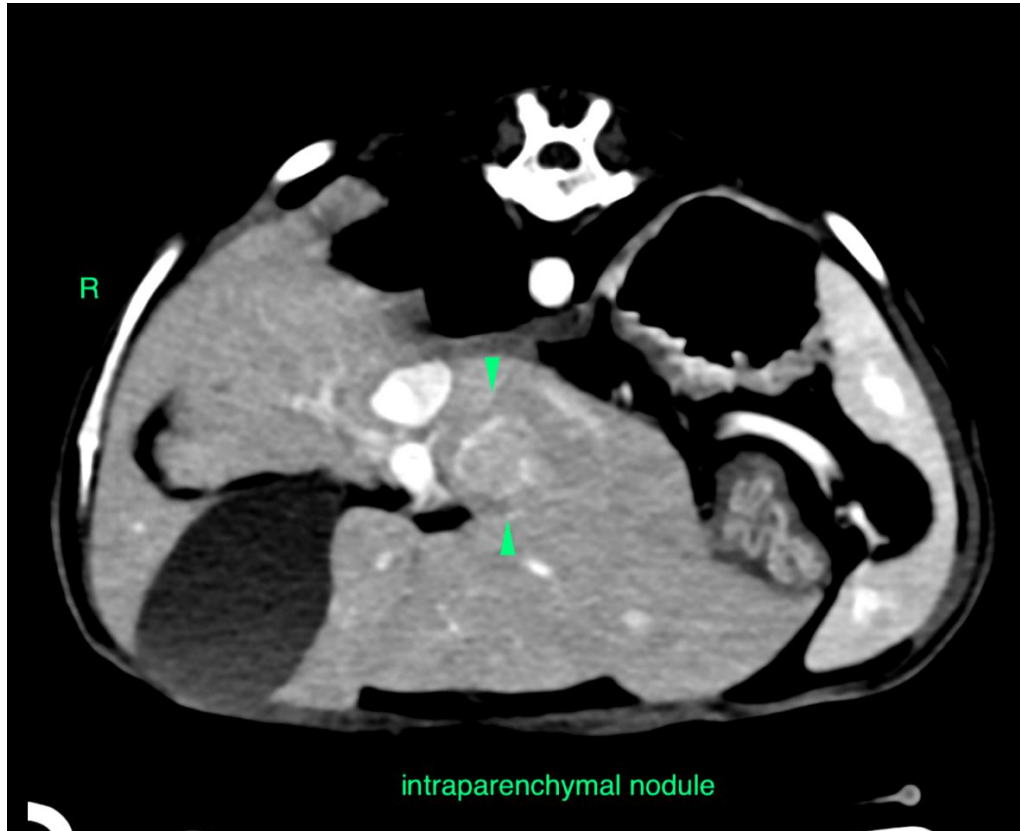
FS

AGE

14

INTERPRETED BY

Sebastian Schaub, DVM
Dr. med. vet. DipECVDI



HOSPITAL NAME

Animal Health
Partners

REFERRING VET

Dr. Ashley Gold

INVOICE

50437

DATE

2-18-22

The information and recommendations provided are based on the images presented by the referring veterinarian/sonographer. No evaluation can be communicated regarding pathology that was not visible in the image/video clips provided.

Thank you for this referral. If the clinical or image interpretation does not parallel your findings or if I can be of any further assistance please contact me.

Sebastian Schaub, Sebastian Schaub, DVM, Dr. med. vet. DipECVDI
sebast.schaub@gmail.com