



PATIENT

Harley Headrick

PRESENTING CLINICAL SIGNS

Approximately one month history of acting painful intermittently when eating
Abnormal PE/Chem/CBC/UA Results: Normal labs

SPECIES

Feline

COMPUTED TOMOGRAPHY OF THE SKULL

A high resolution post-contrast CT study of the skull is provided for review.

BREED

DSH

COMPUTED TOMOGRAPHIC FINDINGS

A supernumerary triadan 106&206 is seen.

SEX

N

The nasal cavity presents the expected aerated spaces between thin & even conchae and turbinates with smooth mucosal lining.

Both temporomandibular joints present congruent joint spaces with even subchondral bone surfaces and are considered within normal limits.

AGE

3 Years

Both tympanic bullae are aerated, the mucosal lining is not seen, the bony wall is smooth and thin. The external ear canals are within normal limits.

The brain presents no deviation from normal anatomy and symmetry. The brain parenchyma is homogeneous and within normal limits for attenuation and distribution of contrast enhancement. The ventricular system is non-dilated and symmetric.

INTERPRETED BY

Sebastian Schaub, DVM
Dr. med. vet. DipECVDI

The submandibular and medial retropharyngeal lymph nodes are small and elongated with a normal short-to-long-axis-ratio is < 0.5, the attenuation and contrast enhancement pattern is uniform.

HOSPITAL NAME

Petroglyph Animal
Hospital

An internal jugular vein is seen on the left side.

COMPUTED TOMOGRAPHIC DIAGNOSIS

- Supernumerary triadan 106&206
- Left sided internal jugular vein, normal anatomical variant

REFERRING VET

Alice Ku

INTERPRETATION OF THE FINDINGS & FURTHER RECOMMENDATIONS

The current CT study of the skull presents without clinically relevant abnormalities. No overt resorptive dental lesions are appreciated, however check clinically if there is evidence of resorptive dental lesions as cause for the pain. Feline orofacial pain syndrome might be a differential as well.

INVOICE

50429

DATE

2-18-22



PATIENT

Harley Headrick

SPECIES

Feline

BREED

DSH

SEX

N

AGE

3 Years

INTERPRETED BY

Sebastian Schaub, DVM
Dr. med. vet. DipECVDI

HOSPITAL NAME

Petroglyph Animal
Hospital

REFERRING VET

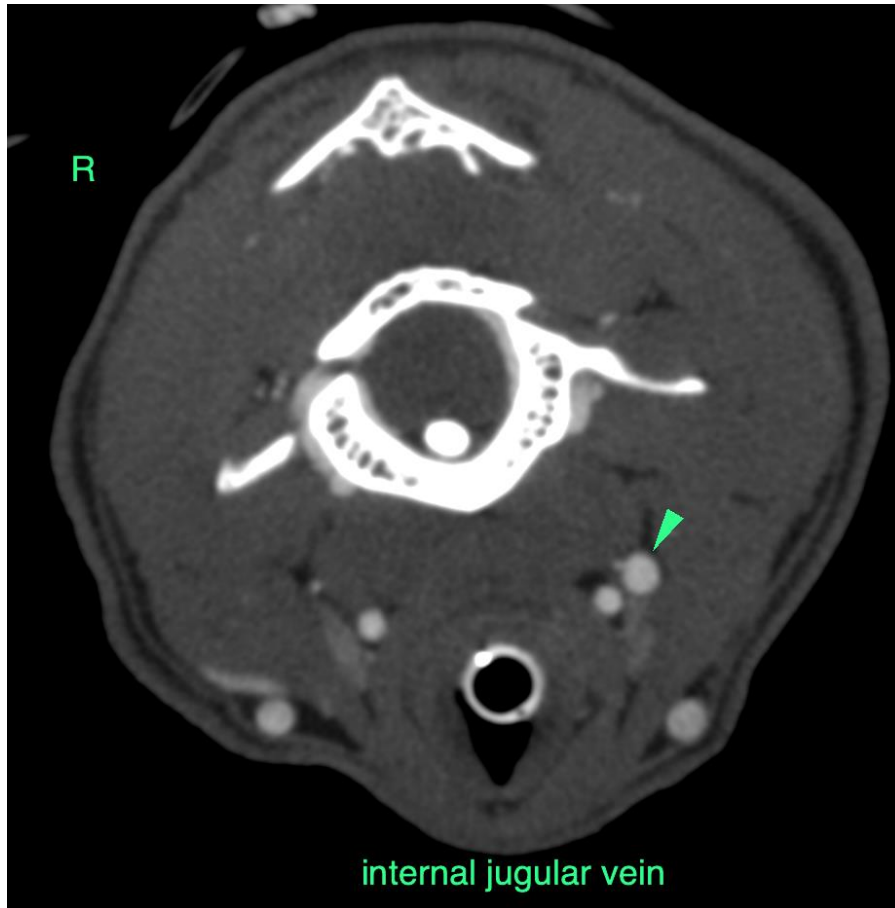
Alice Ku

INVOICE

50429

DATE

2-18-22



The information and recommendations provided are based on the images presented by the referring veterinarian/sonographer. No evaluation can be communicated regarding pathology that was not visible in the image/video clips provided.

Thank you for this referral. If the clinical or image interpretation does not parallel your findings or if I can be of any further assistance please contact me.

Sebastian Schaub, Sebastian Schaub, DVM, Dr. med. vet. DipECVDI
sebast.schaub@gmail.com