



PATIENT

Bentley Foos

SPECIES

Canine

BREED

Terrier Mix

SEX

Neutered Male

AGE

10 Years, 7 Months

INTERPRETED BY

Sebastian Schaub, DVM
Dr. med. vet. DipECVDI

HOSPITAL NAME

Elizabeth Animal
Hospital

REFERRING VET

Leon Anderson, DVM

INVOICE

50443

DATE

2-18-22

PRESENTING CLINICAL SIGNS

Recurrent swelling of interdigital area of left hind foot on ventral aspect between D3 and D4. Foot swollen today. Last night into this morning had an episode of weakness in the rear end and shaking in the rear end. Tired today but eating well. Recurrent right eye corneal ulcer- suspect dystechia.

Abnormal PE/Chem/CBC/UA Results: Right eye: corneal ulcer healing. LH foot swollen and tender- centered at D3-4 ventrum. Proprioception loss- moderate in both hind limbs. Tender spine at TL junction. Concern for foreign body in foot, IVDD in spine, and other reasons for episode last night.

RADIOGRAPHIC STUDY OF THE THORACIC SPINE, ABDOMEN AND HIND PAWS

Radiographs of the thoracic spine, abdomen and hind paws are provided for review.

RADIOGRAPHIC FINDINGS

Thoracic spine

The intervertebral disc space T12/T13 is moderately narrowed.

The osseous and surrounding soft tissue structures of the pictured segments of the thoracic spine are within normal limits.

Abdomen

The surrounding bony structures – including the lumbar spine – are within normal limits.

No abnormalities of the extraabdominal soft tissues are noted. The abdominal wall is smooth and thin.

The serosal detail is maintained throughout the peritoneal and retroperitoneal space.

The liver is appropriate in position, size and presents uniform opacity.

The splenic head is in the anticipated position and within normal limits for size and opacity. The splenic body and tail are considered normal for position, size, shape and opacity.

Both kidneys are seen and present with normal size, shape, delineation and opacity. The urinary bladder is in its anticipated position. No radiopaque calculi are noted throughout the upper and lower urinary tract.

The stomach is in its anticipated position and presents normal content.

The small intestinal loops are of even diameter and non-dilated, a small amount of gas is seen within the small intestinal loops and considered within normal limits.

The colon is seen in the expected position and presents with appropriate content.



PATIENT Left hind paw

Bentley Foos A moderate soft tissue swelling level with the 3rd and 4th phalanx of the left hind paw is appreciated – most accentuated level with the 4th digit. The osseous structures of the left hind paw are within normal limits.

SPECIES **RADIOGRAPHIC DIAGNOSIS**

Canine

- Discopathy T12/T13
- Soft tissue swelling left hind paw, centered on the 4th digit
- Normal thoracic & lumbar spine
- Normal abdomen

BREED

Terrier Mix

INTERPRETATION OF THE FINDINGS & FURTHER RECOMMENDATIONS

SEX

The narrowed intervertebral disc space T12/T13 indicates discopathy ± compressive myelopathy and might explain the acute clinical signs.

Neutered Male

No abnormality is appreciated, explaining the soft tissue swelling of the 3rd&4th digit of the left hind limb. Inflammatory (e.g. foreign body, interdigital furunculosis), traumatic or neoplastic origin are possible. No radiopaque foreign material is appreciated. Ultrasound can be used as advanced imaging modality to screen for foreign material.

AGE

10 Years, 7 Months

INTERPRETED BY

Sebastian Schaub, DVM
Dr. med. vet. DipECVDI

HOSPITAL NAME

Elizabeth Animal Hospital

REFERRING VET

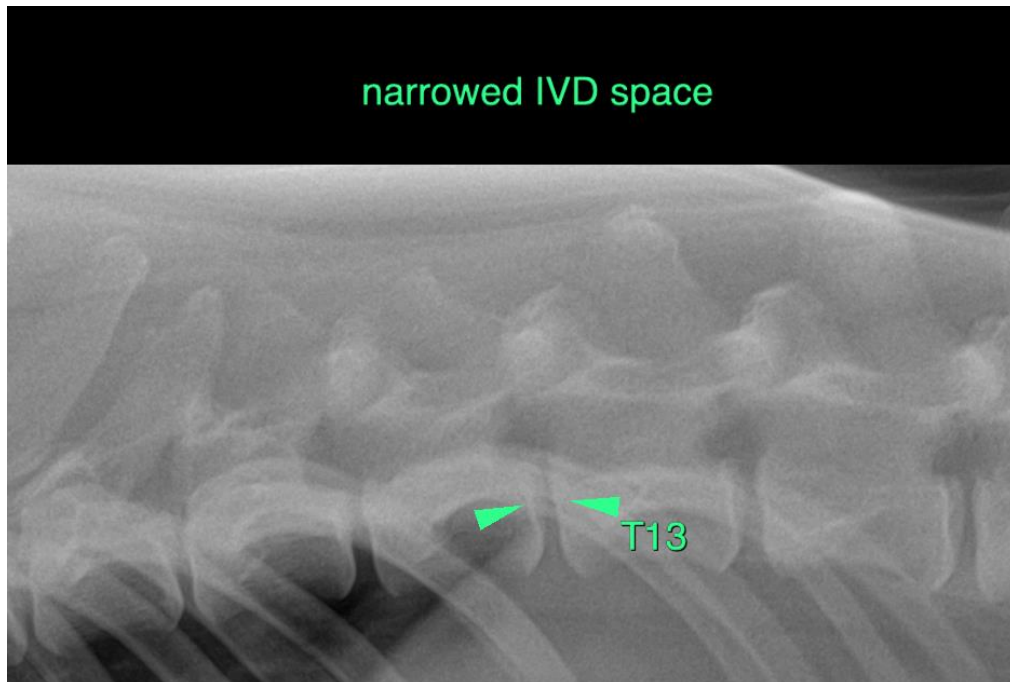
Leon Anderson, DVM

INVOICE

50443

DATE

2-18-22





PATIENT

Bentley Foos

SPECIES

Canine

BREED

Terrier Mix

SEX

Neutered Male

AGE

10 Years, 7 Months

INTERPRETED BY

Sebastian Schaub, DVM
Dr. med. vet. DipECVDI

HOSPITAL NAME

Elizabeth Animal
Hospital

REFERRING VET

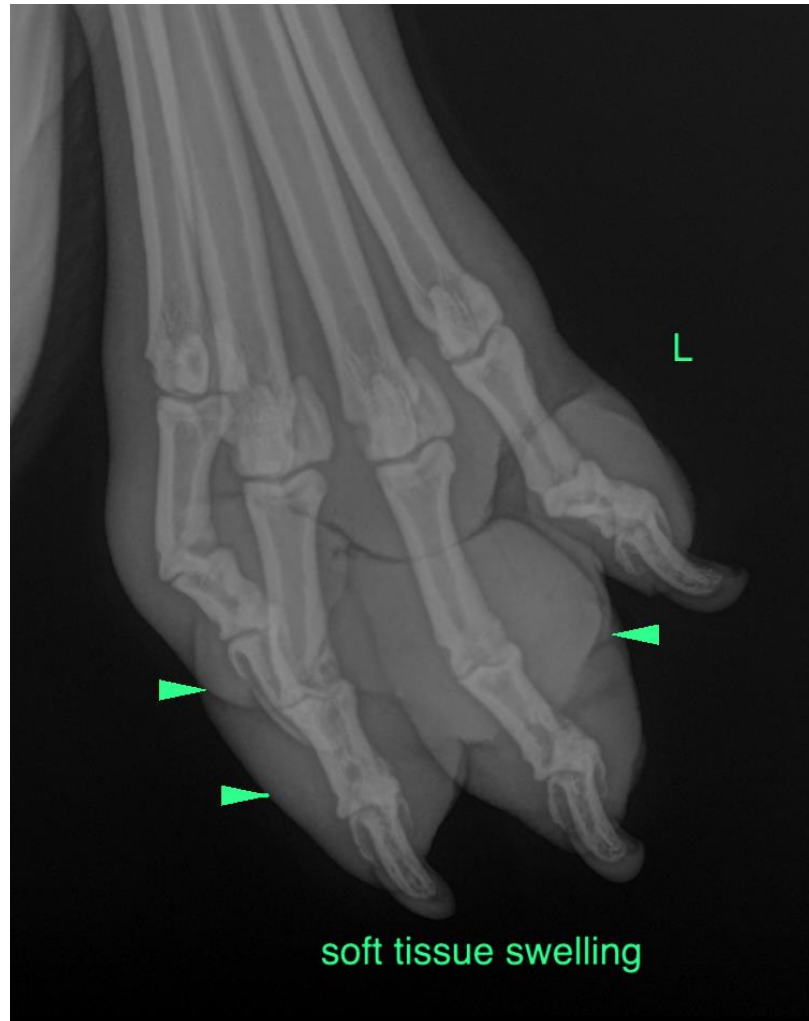Leon Anderson, DVM

INVOICE

50443

DATE

2-18-22



The information and recommendations provided are based on the images presented by the referring veterinarian/sonographer. No evaluation can be communicated regarding pathology that was not visible in the image/video clips provided.

Thank you for this referral. If the clinical or image interpretation does not parallel your findings or if I can be of any further assistance please contact me.

Sebastian Schaub, Sebastian Schaub, DVM, Dr. med. vet. DipECVDI
sebast.schaub@gmail.com