



PATIENT

Rudder Casas-Dolz

SPECIES

Canine

BREED

Mixed

SEX

MN

AGE

5Y, 3M

WEIGHT

74lbs

INTERPRETED BY

Sebastian Schaub, DVM
Dr. med. vet.
DipECVDI

IMAGING PERFORMED BY

Dr Raul Casas

HOSPITAL NAME

State Avenue Vet
Clinic

REFERRING VET

Dr Raul Casas

INVOICE

73806

DATE

2-17-26

PRESENTING CLINICAL SIGNS

- On/off lameness RH after activity; Hx of R tibial Fx as a puppy treated with casting for 2 months

Abnormal PE/Chem/CBC/UA Results: BAR; no lameness at walk or trot; no pain on palpation or manipulation of back, hips, iliopsoas; stifles- no effusion, med buttress or instability; sl thickened R tarsus

COMPUTED TOMOGRAPHY OF THE TARSAL JOINTS

A high resolution plain CT study of the tarsal joints is provided for review.

COMPUTED TOMOGRAPHIC FINDINGS

The periarticular bones of both tarsal joints – including all rows of the tarsal joints – present mild to moderate osteophyte new bone formation. Exostosis formation is seen along the sustentaculum tali bilaterally. Distal to the medial malleolus of the right tarsal joint, multiple small (<2 mm) roundish osseous bodies are seen.

COMPUTED TOMOGRAPHIC DIAGNOSIS

- Osteoarthritis tarsus bilaterally
- Right sided medial malleolar fragmentation versus metaplasia

INTERPRETATION OF THE FINDINGS & FURTHER RECOMMENDATIONS

The CT findings are consistent with degenerative joint disease of both tarsal joints, an underlying cause cannot be specified – traumatic insult is possible. I do not see evidence of fracture nor OCD lesion. If there is evidence of relevant soft tissue swelling of the tarsus, workup can be complemented by a synovial tap.

The medial malleolar fragmentation is commonly a sequela to degenerative joint but has also been described as possible osteochondrosis lesion.



PATIENT

Rudder Casas-Dolz

SPECIES

Canine

BREED

Mixed

SEX

MN

AGE

5Y, 3M

WEIGHT

74lbs

INTERPRETED BY

Sebastian Schaub, DVM
Dr. med. vet.
DipECVDI

IMAGING PERFORMED BY

Dr Raul Casas

HOSPITAL NAME

State Avenue Vet
Clinic

REFERRING VET

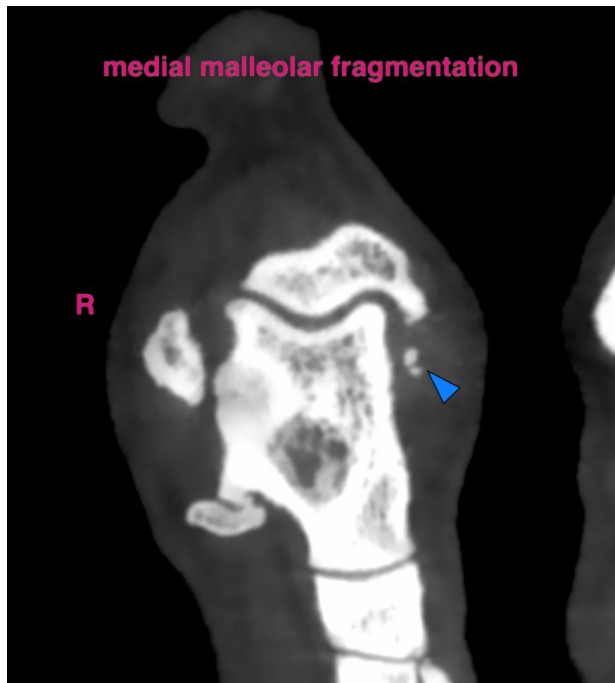
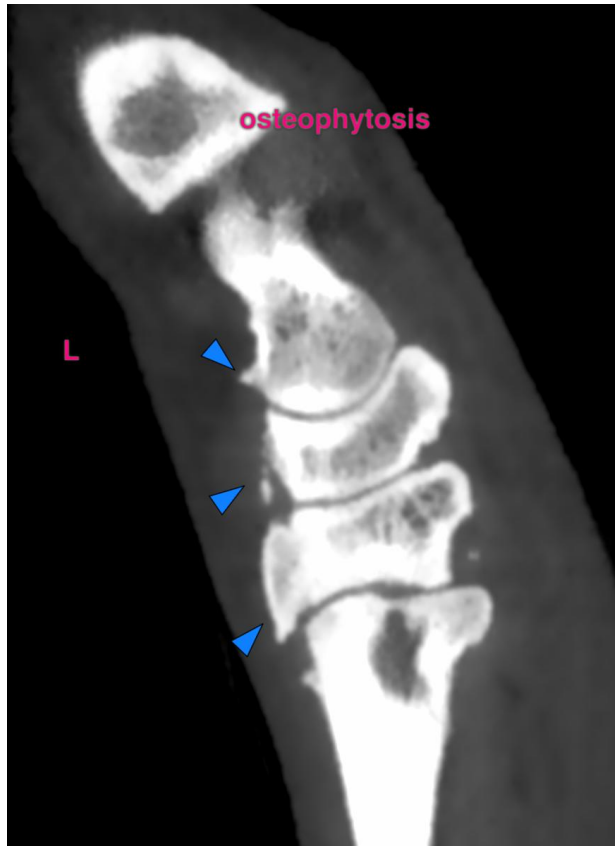
Dr Raul Casas

INVOICE

73806

DATE

2-17-26





PATIENT

Rudder Casas-Dolz

SPECIES

Canine

BREED

Mixed

SEX

MN

AGE

5Y, 3M

WEIGHT

74lbs

INTERPRETED BY

Sebastian Schaub, DVM
Dr. med. vet.
DipECVDI

IMAGING PERFORMED BY

Dr Raul Casas

HOSPITAL NAME

State Avenue Vet
Clinic

REFERRING VET

Dr Raul Casas

INVOICE

73806

DATE

2-17-26

The information and recommendations provided are based on the images presented by the referring veterinarian/sonographer. No evaluation can be communicated regarding pathology that was not visible in the image/video clips provided.

Thank you for this referral. If the clinical or image interpretation does not parallel your findings or if I can be of any further assistance please contact me.

Sebastian Schaub, Sebastian Schaub, DVM, Dr. med. vet. DipECVDI
info@sonopath.com