



PATIENT PRESENTING CLINICAL SIGNS

Tyson Benzoni History: Vomiting and diarrhea and lethargy for the past 2 days after possibly ingesting a foreign object outside.

SPECIES Abnormal PE/Chem/CBC/UA Results: 10-12% dehydrated, all else WNL. CBC/Chem pending.

Canine **RADIOGRAPHIC STUDY OF THE ABDOMEN**

Radiographs of the thorax in three imaging planes are provided for review.

BREED RADIOGRAPHIC FINDINGS

Dachshund The surrounding bony structures are within normal limits.

SEX No abnormalities of the extraabdominal soft tissues are noted. The abdominal wall is smooth and thin.

Neutered Male The serosal detail is maintained throughout the peritoneal and retroperitoneal space.

AGE The liver is appropriate in position, size and presents uniform opacity.

6 Years 8 Months The splenic head is in the anticipated position and within normal limits for size and opacity. The splenic body and tail are considered normal for position, size, shape and opacity.

INTERPRETED BY Both kidneys are seen and present with normal size, shape, delineation and opacity. The urinary bladder is in its anticipated position. No radiopaque calculi are noted throughout the upper and lower urinary tract.

Sebastian Schaub, DVM Dr. med. vet. DipECVDI The stomach is in its anticipated position and contains a small amount of fluid.

HOSPITAL NAME The duodenum is mildly distended by gas. The small intestinal loops are of even diameter and non-dilated, a small amount of gas is seen within the small intestinal loops and considered within normal limits.

Northvale VC The colon is seen in the expected position and empty.

REFERRING VET RADIOGRAPHIC DIAGNOSIS

- Dr. Stefanie Simon
- Mild fluid filled stomach
 - Empty colon

INVOICE INTERPRETATION OF THE FINDINGS & FURTHER RECOMMENDATIONS

21184 The fluid pattern of the stomach and the empty colon in combination with the presenting clinical signs is suggestive for gastroenteritis. There is no evidence of radiopaque foreign material or signs

DATE

2/17/23



PATIENT

for gastrointestinal mechanical obstruction. If clinical signs are refractory to therapy, recommend follow up radiographs or a complete abdominal ultrasound examination.

Tyson Benzoni

SPECIES

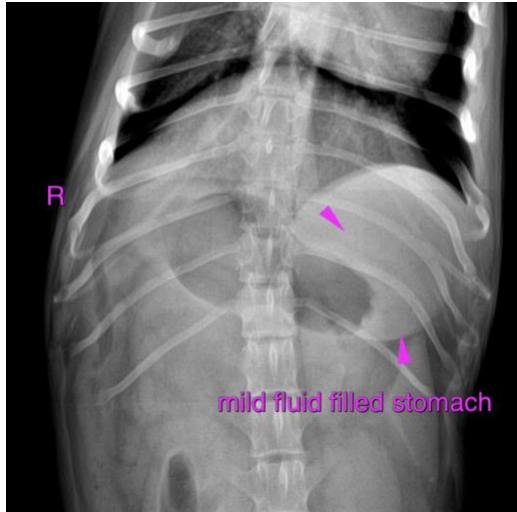
Canine

BREED

Dachshund

SEX

Neutered Male



AGE

6 Years 8 Months

The information and recommendations provided are based on the images presented by the referring veterinarian/sonographer. No evaluation can be communicated regarding pathology that was not visible in the image/video clips provided.

INTERPRETED BY

Sebastian Schaub,
DVM Dr. med. vet.
DipECVDI

Thank you for this referral. If the clinical or image interpretation does not parallel your findings or if I can be of any further assistance please contact me.

Sebastian Schaub, Sebastian Schaub, DVM, Dr. med. vet. DipECVDI
sebast.schaub@gmail.com

HOSPITAL NAME

Northvale VC

REFERRING VET

Dr. Stefanie Simon

INVOICE

21184

DATE

2/17/23