



**PATIENT PRESENTING CLINICAL SIGNS**

**Inigo Gonzales** History: Chronic vomiter 2-3 times a week but more recently for 2-3 days has vomited 5 times. Still seems to have an appetite. Referred to us for gastroscopy for a 2 cm stomach wall mass that was seen with ultrasound by the referring vet. Some air was used to dilate stomach for the gastroscopy but no obvious masses were seen; there was some food stuff. This was done immediately prior to the CT scan and only some of the stomach air was evacuated following the scoping.

**SPECIES**

Canine

Abnormal PE/Chem/CBC/UA Results: Bloodwork from the rDVM showed hemoconcentration and mild hyperalbuminemia

**BREED**

Chihuahua

**COMPUTED TOMOGRAPHIC STUDY OF THE ABDOMEN**

A high-resolution post-contrast CT study of the abdomen is provided for review.

**SEX**

Neutered Male

**COMPUTED TOMOGRAPHIC FINDINGS**

The serosal fat presents normal attenuation behavior. There is no evidence of peritoneal effusion or peritonitis.

**AGE**

6 Years

Both kidneys present within normal limits for size, shape and organ architecture. After contrast administration a bilaterally symmetric and uniform nephro- and pyelogram is noted.

The adrenal glands are within normal limits for size, shape and organ architecture.

**INTERPRETED BY**

Sebastian Schaub,  
DVM Dr. med. vet.  
DipECVDI

Both liver and spleen present with normal shape, even surface, uniformly attenuating parenchyma and homogeneous contrast enhancement, unremarkable.

The portal vein presents a normal order of its tributary veins and intrahepatic branching. No abnormal vessel is noted inside and outside of the liver parenchyma.

**HOSPITAL NAME**

Petroglyph AH

The pancreas is evenly contoured, the pancreatic parenchyma is homogeneous and presents uniform contrast enhancement.

**REFERRING VET**

Dr. Alice Ku

The position, delineation, wall and content of the gastrointestinal tract are considered within normal limits throughout.

The bony and surrounding soft tissue structures reveal no abnormalities.

**COMPUTED TOMOGRAPHIC DIAGNOSIS**

**INVOICE**

21186

- Normal abdomen

**INTERPRETATION OF THE FINDINGS & FURTHER RECOMMENDATIONS**

**DATE**

2/17/23



**PATIENT**

Inigo Gonzales

The CT study of the abdomen presents without abnormalities, no mural gastric mass can be appreciated. No underlying cause for the history of vomiting can be identified.

**SPECIES**

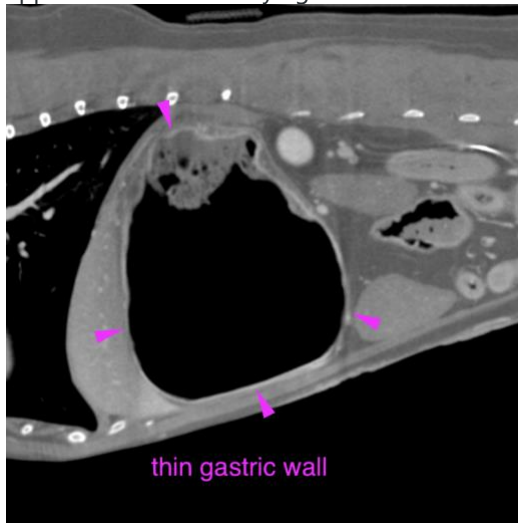
Canine

**BREED**

Chihuahua

**SEX**

Neutered Male



**AGE**

6 Years

**The information and recommendations provided are based on the images presented by the referring veterinarian/sonographer. No evaluation can be communicated regarding pathology that was not visible in the image/video clips provided.**

Thank you for this referral. If the clinical or image interpretation does not parallel your findings or if I can be of any further assistance please contact me.

**INTERPRETED BY**

Sebastian Schaub,  
DVM Dr. med. vet.  
DipECVDI

**Sebastian Schaub**, Sebastian Schaub, DVM, Dr. med. vet. DipECVDI  
sebast.schaub@gmail.com

**HOSPITAL NAME**

Petroglyph AH

**REFERRING VET**

Dr. Alice Ku

**INVOICE**

21186

**DATE**

2/17/23