SonoPath Teleradiology

EDUCATIONAL TELECONSULTATION SERVICES™

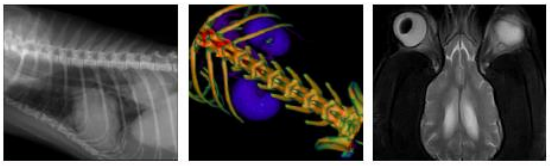

SonoPath.com
1-800-838-4268 info@sonopath.com

PATIENT

Roxy Sisarath

SPECIES

Canine

BREED

Miniature Pinscher Mix

SEX

Female

AGE

12 Years

INTERPRETED BY

Sebastian Schaub, DVM
Dr. med. vet. DipECVDI

HOSPITAL NAME

St. Catherine's Animal Hospital

REFERRING VET

Dr. Boctor

INVOICE

50501

DATE

2-17-22

PRESENTING CLINICAL SIGNS

Lethargic and reduced appetite (Resending as per request)
Abnormal PE/Chem/CBC/UA Results: Bloodwork unremarkable

RADIOGRAPHIC STUDY OF THE THORAX & ABDOMEN

An overview study including the thorax and abdomen in three imaging planes are provided for review.

RADIOGRAPHIC FINDINGS

Thorax

The intervertebral disc space C6/C7 is collapsed and the vertebral endplates present moderate to marked spondylosis formation.

The extrathoracic soft tissues present homogeneous without abnormalities.

The heart is of normal size and shape, there is no evidence of cardiac chamber or vascular enlargement. The pulmonary vasculature is within normal limits.

The cranial mediastinum presents the expected soft tissue opacity. The mediastinal width is less than twice the width of the vertebral column at the same level.

The trachea is normal in diameter and presents the anticipated course. The luminal outline of the trachea is smooth.

The bronchial tree presents with thin walls and tapers uniformly towards the periphery as expected.

The lung parenchyma presents the expected architecture and opacity; the intrapulmonary vascular branching is seen up to the third order lung vessels.

The diaphragm is well delineated with even surface and the expected mild cranial bulging of the diaphragmatic cupola.

Abdomen

The intervertebral disc spaces T13/L1 and L1/L2 are moderately to markedly narrowed. The vertebral endplates L1/L2 present moderate spondylosis formation. Mineral opaque material is superimposed on the ventral aspect of the neuroforamen L1/L2.

No abnormalities of the extraabdominal soft tissues are noted. The abdominal wall is smooth and thin.

The serosal detail is maintained throughout the peritoneal and retroperitoneal space.

The liver is appropriate in position, size and presents uniform opacity.

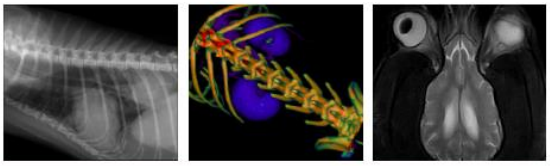

SonoPath.com
1-800-838-4268 info@sonopath.com

PATIENT

Roxy Sisarath

SPECIES

Canine

BREED

Miniature Pinscher Mix

SEX

Female

AGE

12 Years

INTERPRETED BY

Sebastian Schaub, DVM
Dr. med. vet. DipECVDI

HOSPITAL NAME

St. Catherine's Animal Hospital

REFERRING VET

Dr. Boctor

INVOICE

50501

DATE

2-17-22

The splenic head is in the anticipated position and within normal limits for size and opacity. The splenic body and tail are considered normal for position, size, shape and opacity.

Both kidneys are seen and present with normal size, shape, delineation and opacity. The urinary bladder is in its anticipated position. No radiopaque calculi are noted throughout the upper and lower urinary tract.

The stomach is in its anticipated position. A small metal opaque foreign body (2 x 4 mm) is seen in the stomach.

The small intestinal loops are of even diameter and non-dilated, a small amount of gas is seen within the small intestinal loops and considered within normal limits.

The colon is seen in the expected position and presents with appropriate content.

RADIOGRAPHIC DIAGNOSIS

- Chronic discopathy C6/C7, T13/L1 and L1/L2 with osseous remodeling of the vertebral endplates
- Intervertebral disc protrusion L1/L2 versus lateral spondylosis formation
- Small metal opaque gastric foreign body

INTERPRETATION OF THE FINDINGS & FURTHER RECOMMENDATIONS

The radiographic study of the thorax & abdomen presents no abnormalities, explaining the current clinical signs. Rule out pain originating from the neck or lumbar spine as source for the clinical signs as well.

SonoPath Teleradiology

EDUCATIONAL TELECONSULTATION SERVICES™

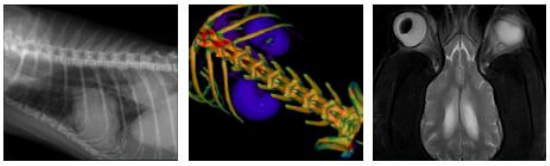

SonoPath.com
1-800-838-4268 info@sonopath.com

PATIENT

Roxy Sisarath

SPECIES

Canine

BREED

Miniature Pinscher Mix

SEX

Female

AGE

12 Years

INTERPRETED BY

Sebastian Schaub, DVM
Dr. med. vet. DipECVDI

HOSPITAL NAME

St. Catherine's Animal Hospital

REFERRING VET

Dr. Boctor

INVOICE

50501

DATE

2-17-22

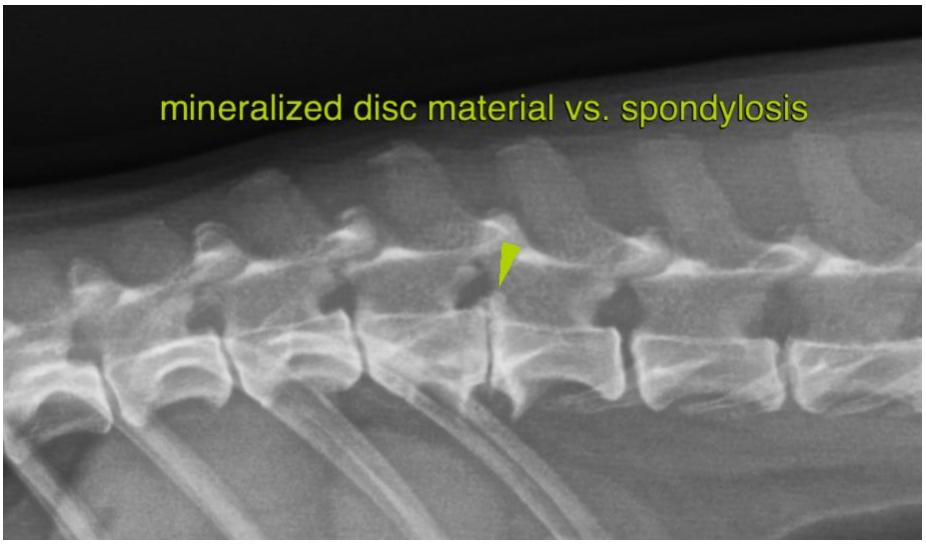

SonoPath Teleradiology

EDUCATIONAL TELECONSULTATION SERVICES™

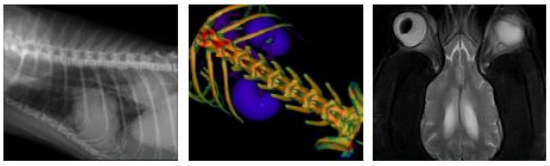

SonoPath.com
1-800-838-4268 info@sonopath.com

PATIENT

Roxy Sisarath

SPECIES

Canine

BREED

Miniature Pinscher Mix

SEX

Female

AGE

12 Years

INTERPRETED BY

Sebastian Schaub, DVM
Dr. med. vet. DipECVDI

HOSPITAL NAME

St. Catherine's Animal Hospital

REFERRING VET

Dr. Boctor

INVOICE

50501

DATE

2-17-22

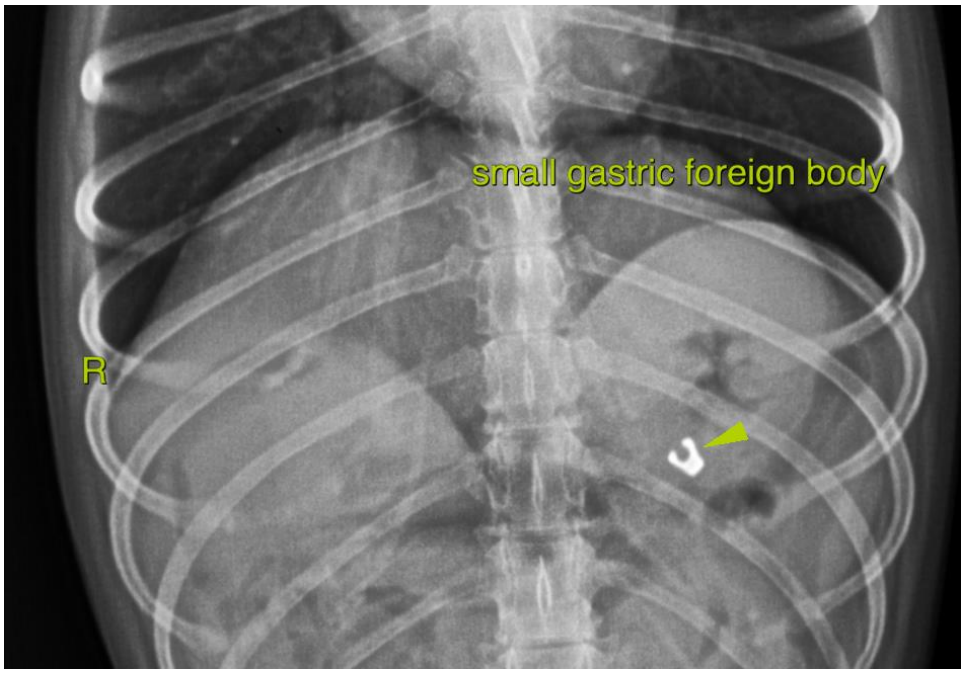

The information and recommendations provided are based on the images presented by the referring veterinarian/sonographer. No evaluation can be communicated regarding pathology that was not visible in the image/video clips provided.

Thank you for this referral. If the clinical or image interpretation does not parallel your findings or if I can be of any further assistance please contact me.

Sebastian Schaub, Sebastian Schaub, DVM, Dr. med. vet. DipECVDI
sebast.schaub@gmail.com