

**PATIENT**

Rolo Shniderman

PRESENTING CLINICAL SIGNS

History of intermittent limping on the left hindlimb
Abnormal PE/Chem/CBC/UA Results: Decreased range of motion on the left hindlimb Mild limping/gait changes to the left hindlimb

SPECIES

Canine

RADIOGRAPHIC STUDY OF THE PELVIS AND STIFLE JOINTS

Radiographs of the pelvis and stifle joints in two orthogonal imaging planes are provided for review.

BREED

Goldendoodle Mini

RADIOGRAPHIC FINDINGS

The osseous and surrounding soft tissue structures of the pelvis are within normal limits. Both coxofemoral joints present smooth osseous margins and a congruent joint space, unremarkable.

SEX

Male Neutered

The patella of the left stifle joint is seen medial to the medial femoral condyle. The left stifle joint presents mild intracapsular soft tissue swelling. The osseous margins of both stifle joints are smooth. A soft tissue opaque nodule is superimposed on the proximal left tibia in the mediolateral projection – check for cutaneous nodules.

AGE

2

INTERPRETED BY

Sebastian Schaub, DVM
Dr. med. vet. DipECVDI

RADIOGRAPHIC DIAGNOSIS

- Left sided medial patellar luxation
- Mild articular swelling left stifle joint
- Normal pelvis & coxofemoral joints

INTERPRETATION OF THE FINDINGS & FURTHER RECOMMENDATIONS

The medial patellar luxation can explain the intermittent lameness in the left hind limb. Secondary mild joint effusion of the left stifle joint. Surgical correction is a feasible treatment option.

HOSPITAL NAME

Boca Park Animal
Hospital

REFERRING VET

Tifanie Silver

INVOICE

50390

DATE

2-17-22



PATIENT

Rolo Shniderman

SPECIES

Canine

BREED

Goldendoodle Mini

SEX

Male Neutered

AGE

2

INTERPRETED BY

Sebastian Schaub, DVM
Dr. med. vet. DipECVDI

HOSPITAL NAME

Boca Park Animal
Hospital

REFERRING VET

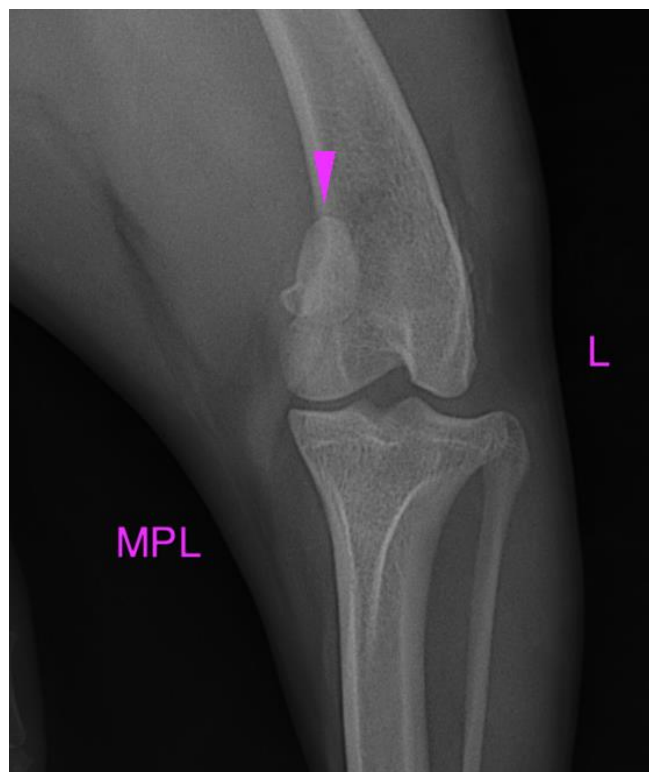
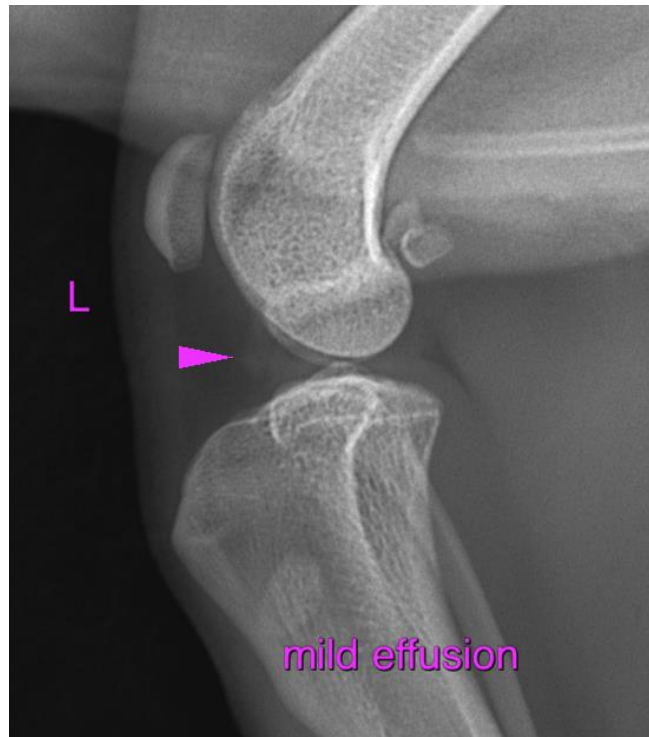
Tifanie Silver

INVOICE

50390

DATE

2-17-22





PATIENT

Rolo Shniderman

The information and recommendations provided are based on the images presented by the referring veterinarian/sonographer. No evaluation can be communicated regarding pathology that was not visible in the image/video clips provided.

SPECIES

Canine

Thank you for this referral. If the clinical or image interpretation does not parallel your findings or if I can be of any further assistance please contact me.

BREED

Goldendoodle Mini

Sebastian Schaub, Sebastian Schaub, DVM, Dr. med. vet. DipECVDI
sebast.schaub@gmail.com

SEX

Male Neutered

AGE

2

INTERPRETED BY

Sebastian Schaub, DVM
Dr. med. vet. DipECVDI

HOSPITAL NAME

Boca Park Animal
Hospital

REFERRING VET

Tifanie Silver

INVOICE

50390

DATE

2-17-22