



PATIENT PRESENTING CLINICAL SIGNS

Pippi Ayson chronic low grade non regenerative anemia vomiting small amount of blood treated with metronidazole/gabapentin by the referring vet
 Abnormal PE/Chem/CBC/UA Results: 10feb pcv 25% reticulocytes wnl - mchc high - alt mild elevation coag study has been sent to the lab

SPECIES

Canine

COMPUTED TOMOGRAPHY OF THE SKULL

A high resolution pre- and post-contrast CT study of the skull is provided for review.

BREED

Shih Tzu

COMPUTED TOMOGRAPHIC FINDINGS

Multiple teeth are absent.

SEX

Female

The right ocular bulb is absent.

The nasal cavity presents the expected aerated spaces between thin & even conchae and turbinates with smooth mucosal lining.

AGE

12

Both temporomandibular joints present congruent joint spaces with even subchondral bone surfaces and are considered within normal limits.

INTERPRETED BY

Sebastian Schaub, DVM
 Dr. med. vet. DipECVDI

Both tympanic bullae are aerated, the mucosal lining is not seen, the bony wall is smooth and thin. The external ear canals are within normal limits.

Post contrast administration, centered on the osseous tentorium, a strong contrast enhancing, roundish mass is visible, measuring approximately 12 x 15 x 11 mm in size.

HOSPITAL NAME

Advanced Veterinary
 Imaging

The submandibular and medial retropharyngeal lymph nodes are small and elongated with a normal short-to-long-axis-ratio is < 0.5, the attenuation and contrast enhancement pattern is uniform.

COMPUTED TOMOGRAPHIC DIAGNOSIS

REFERRING VET

Eamon Ryan

- Intracranial extraaxial mass centered on the osseous tentorium of the cerebellum
- Multiple absent teeth
- History of right sided enucleation of the ocular bulb

INTERPRETATION OF THE FINDINGS & FURTHER RECOMMENDATIONS

INVOICE

50359

The extraaxial mass is concerning for primary neoplasia, such as meningioma, round cell tumor, metastasis. Granuloma is a differential as well but considered less likely. Complementing workup by a CSF tap is recommended for further workup.

DATE

2-16-22



PATIENT

Pippi Ayson

SPECIES

Canine

BREED

Shih Tzu

SEX

Female

AGE

12

INTERPRETED BY

Sebastian Schaub, DVM
Dr. med. vet. DipECVDI

HOSPITAL NAME

Advanced Veterinary
Imaging

REFERRING VET

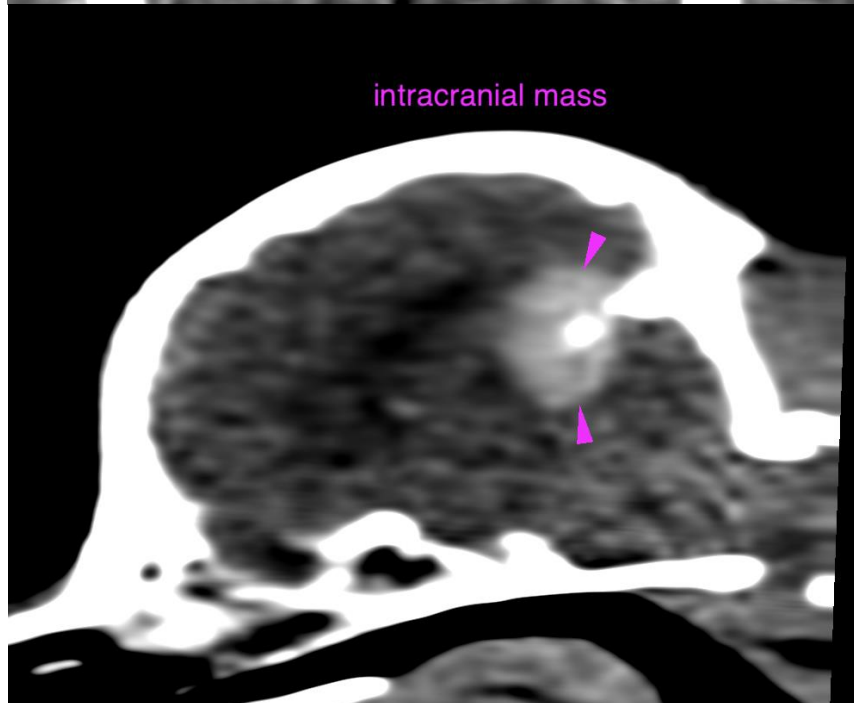
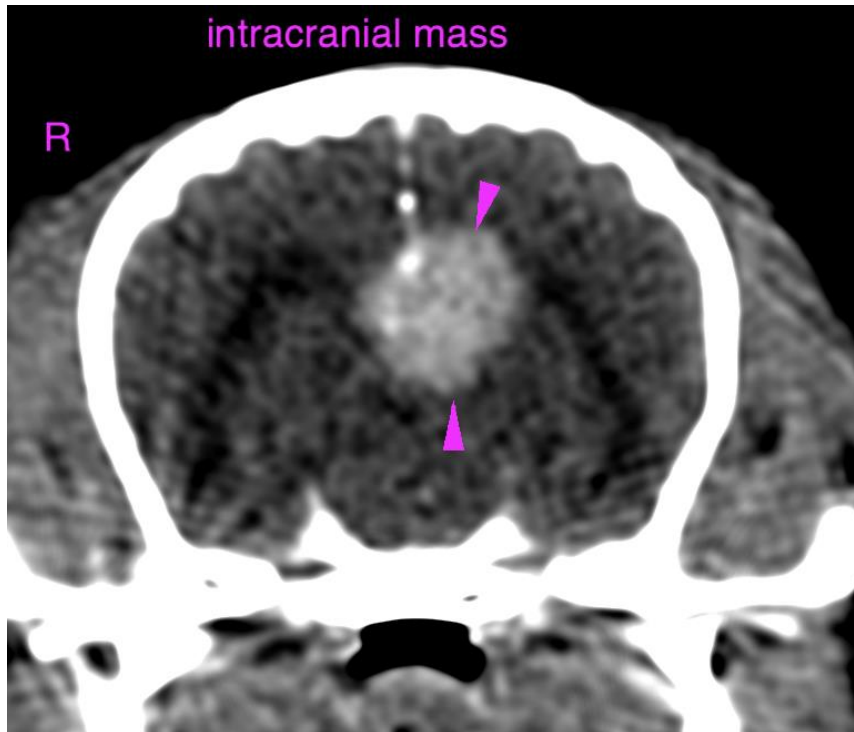
Eamon Ryan

INVOICE

50359

DATE

2-16-22





PATIENT

Pippi Ayson

The information and recommendations provided are based on the images presented by the referring veterinarian/sonographer. No evaluation can be communicated regarding pathology that was not visible in the image/video clips provided.

SPECIES

Canine

Thank you for this referral. If the clinical or image interpretation does not parallel your findings or if I can be of any further assistance please contact me.

Sebastian Schaub, Sebastian Schaub, DVM, Dr. med. vet. DipECVDI
sebast.schaub@gmail.com

BREED

Shih Tzu

SEX

Female

AGE

12

INTERPRETED BY

Sebastian Schaub, DVM
Dr. med. vet. DipECVDI

HOSPITAL NAME

Advanced Veterinary
Imaging

REFERRING VET

Eamon Ryan

INVOICE

50359

DATE

2-16-22