



PATIENT

Olive Torres

PRESENTING CLINICAL SIGNS

Acute onset wet cough. No heart murmur. Generalized crackles. No fever.

SPECIES

K9

RADIOGRAPHIC STUDY OF THE THORAX

Radiographs of the thorax in three imaging planes are provided for review.

BREED

Yorkshire Terrier

The surrounding bony structures are within normal limits.

SEX

Male Neutered

The extrathoracic soft tissues present homogeneous without abnormalities.

The heart is of normal size and shape, there is no evidence of cardiac chamber or vascular enlargement. The pulmonary vasculature is within normal limits.

AGE

8 Years

The cranial mediastinum presents the expected soft tissue opacity. The mediastinal width is less than twice the width of the vertebral column at the same level.

The intrathoracic segment of the trachea presents a mild to moderate decreased diameter.

In the right lateral projection of the thorax – during expiration – the carina of the tracheal and principal bronchi are collapsed – in the left lateral projection the carina and principal bronchi present with the expected diameter.

INTERPRETED BY

Sebastian Schaub, DVM
Dr. med. vet. DipECVDI

The lung parenchyma presents the expected architecture and opacity; the intrapulmonary vascular branching is seen up to the third order lung vessels.

The diaphragm is well delineated with even surface and the expected mild cranial bulging of the diaphragmatic cupola.

HOSPITAL NAME

DTLAvets

RADIOGRAPHIC DIAGNOSIS

REFERRING VET

Dr. Castaneda

- Bronchial collapse
- Mild to moderate tracheal collapse, intrathoracic segment

INTERPRETATION OF THE FINDINGS & FURTHER RECOMMENDATIONS

The main finding is the bronchial collapse, which is a plausible source for the cough. No abnormalities of the lung parenchyma are appreciated. However, if there is suspicion for accompanying bronchopneumonia, follow up radiographs are recommended, as radiographic changes lack behind clinical signs.

INVOICE

50327

DATE

2-16-22



PATIENT

Olive Torres

SPECIES

K9

BREED

Yorkshire Terrier

SEX

Male Neutered

AGE

8 Years

INTERPRETED BY

Sebastian Schaub, DVM
Dr. med. vet. DipECVDI

HOSPITAL NAME

DTLAvets

REFERRING VET

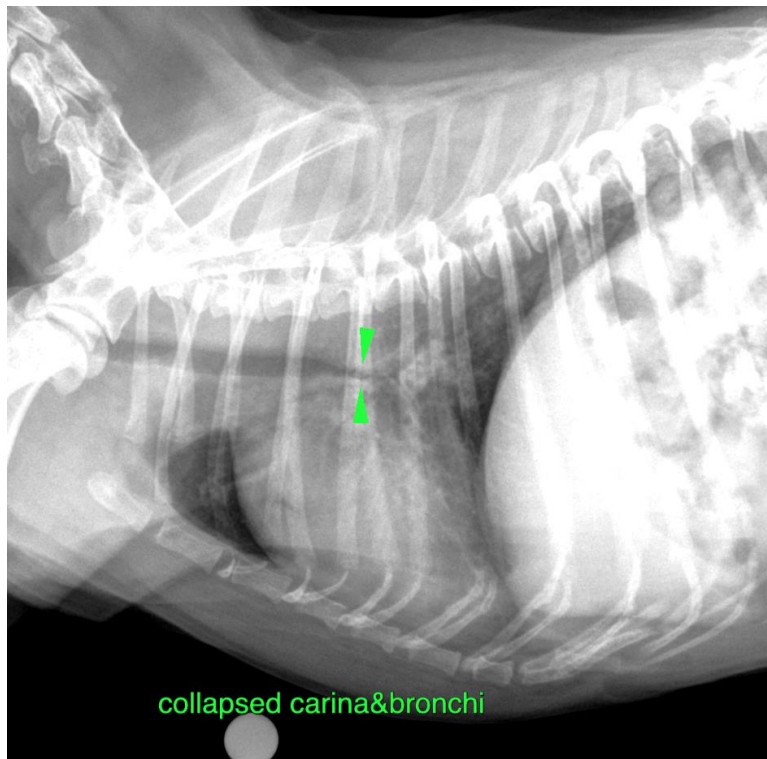
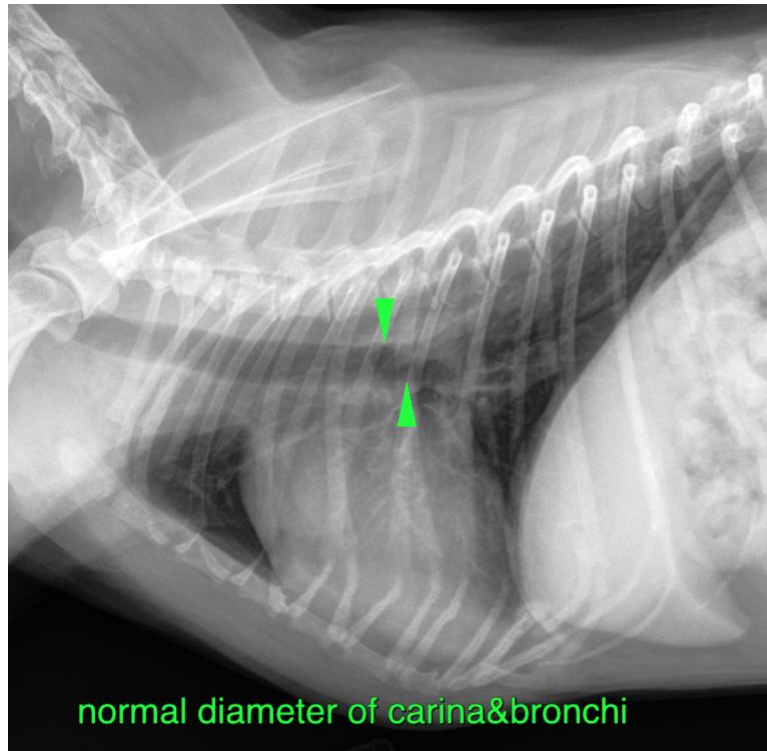
Dr. Castaneda

INVOICE

50327

DATE

2-16-22





PATIENT

Olive Torres

The information and recommendations provided are based on the images presented by the referring veterinarian/sonographer. No evaluation can be communicated regarding pathology that was not visible in the image/video clips provided.

SPECIES

K9

Thank you for this referral. If the clinical or image interpretation does not parallel your findings or if I can be of any further assistance please contact me.

BREED

Yorkshire Terrier

Sebastian Schaub, Sebastian Schaub, DVM, Dr. med. vet. DipECVDI
sebast.schaub@gmail.com

SEX

Male Neutered

AGE

8 Years

INTERPRETED BY

Sebastian Schaub, DVM
Dr. med. vet. DipECVDI

HOSPITAL NAME

DTLAvets

REFERRING VET

Dr. Castaneda

INVOICE

50327

DATE

2-16-22