

**PATIENT**

Nani Lewis

PRESENTING CLINICAL SIGNS

Patient presented for possible bite on right forepaw, owner states was at a park and lifted paw and started shaking it. Extremely painful on digital palpation. Also suspect arthritis
Abnormal PE/Chem/CBC/UA Results: BW performed 2 weeks ago, mild increase in ALT otherwise normal

SPECIES

Canine

RADIOGRAPHIC STUDY OF THE FRONT LIMBS BILATERALLY

Radiographs of the front limbs in two imaging planes are provided for review.

BREED

Yorkshire Terrier

RADIOGRAPHIC FINDINGS

Both shoulder joints present smooth osseous margins, no abnormalities of the surrounding soft tissue structures are appreciated.

SEX

FS

The elbow joints present moderate osteophyte new bone formation.

A wart like soft opaque lesion is seen at the medial aspect of the right antebrachium.

AGE

15

The carpal joints are within normal limits.

A mild soft tissue swelling of the right front paw – accentuated level with the 5th phalanx is noted. The osseous structures of the front paws present no abnormalities.

INTERPRETED BY

Sebastian Schaub, DVM
Dr. med. vet. DipECVDI

RADIOGRAPHIC DIAGNOSIS

- Soft tissue swelling region of the fifth digit right front limb
- Advanced degenerative osteoarthritis elbow joints bilaterally
- Normal shoulder & carpal joints bilaterally.

HOSPITAL NAME

Boca Park Animal
Hospital

INTERPRETATION OF THE FINDINGS & FURTHER RECOMMENDATIONS

The soft tissue swelling in the region of the fifth digit of the right front paw can be a sequela to traumatic insult (potential bite injury), inflammatory (e.g. insect bite) or due to the acute onset unlikely neoplastic in origin. There is no evidence of fracture.

REFERRING VET

Dr. Corinna Gorgon

INVOICE

50366

DATE

2-16-22



PATIENT

Nani Lewis

SPECIES

Canine

BREED

Yorkshire Terrier

SEX

FS

AGE

15

INTERPRETED BY

Sebastian Schaub, DVM
Dr. med. vet. DipECVDI

HOSPITAL NAME

Boca Park Animal
Hospital

REFERRING VET

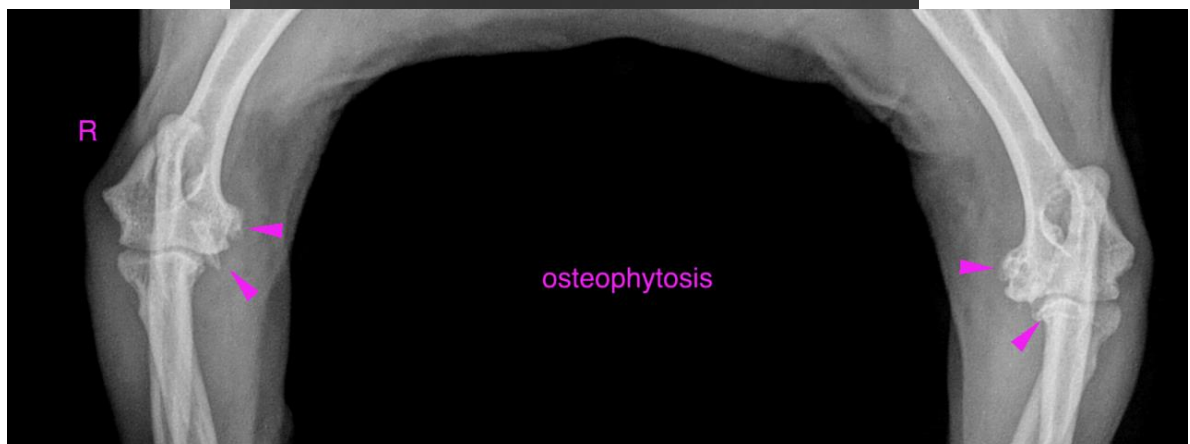
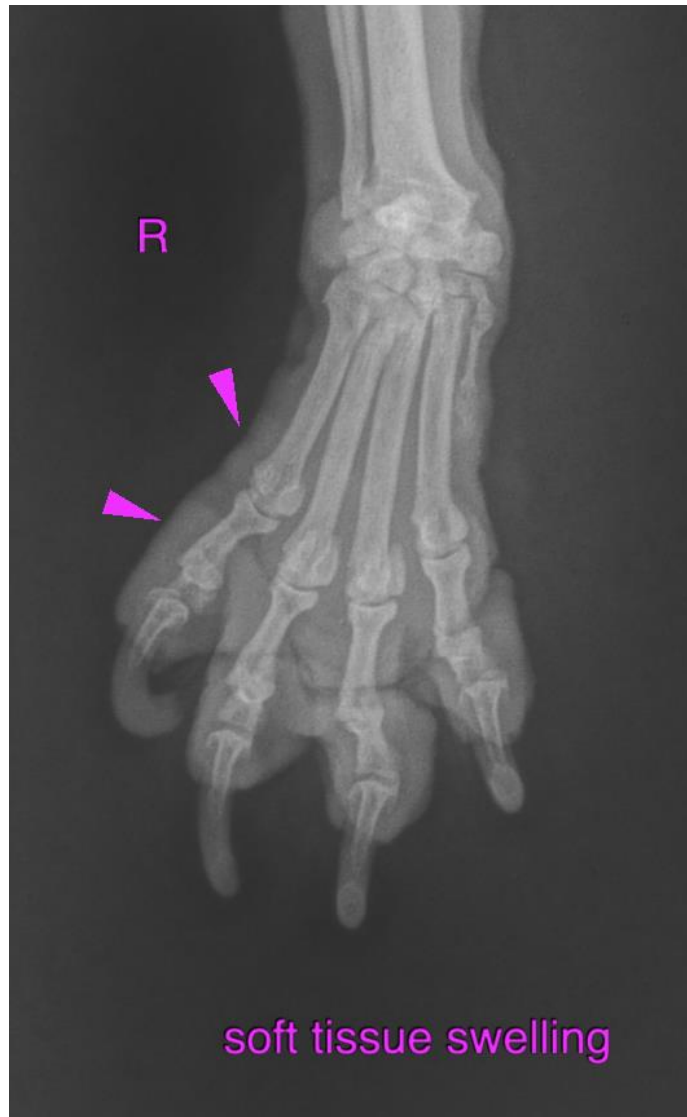Dr. Corinna Gorgon

INVOICE

50366

DATE

2-16-22





PATIENT

Nani Lewis

SPECIES

Canine

The information and recommendations provided are based on the images presented by the referring veterinarian/sonographer. No evaluation can be communicated regarding pathology that was not visible in the image/video clips provided.

BREED

Yorkshire Terrier

Thank you for this referral. If the clinical or image interpretation does not parallel your findings or if I can be of any further assistance please contact me.

Sebastian Schaub, Sebastian Schaub, DVM, Dr. med. vet. DipECVDI
sebast.schaub@gmail.com

SEX

FS

AGE

15

INTERPRETED BY

Sebastian Schaub, DVM
Dr. med. vet. DipECVDI

HOSPITAL NAME

Boca Park Animal
Hospital

REFERRING VET

Dr. Corinna Gorgon

INVOICE

50366

DATE

2-16-22