



**PATIENT PRESENTING CLINICAL SIGNS**

**PATIENT** Kittle Daniel

**SPECIES** Feline

**BREED** DSH

**SEX** CM

**AGE** 16 Years

**INTERPRETED BY** Sebastian Schaub, DVM  
Dr. med. vet. DipECVDI

Kittle presented with a 3 month history of intermittent wheezing and labored breathing. He presented on 1/28/22 for annual wellness workup. Bilateral otitis external and media was diagnosed and he was treated with Posatex otic suspension and an ear wash. Kittle began sneezing after the 1/28/22 appointment. Sneezing progressed to mucopurulent nasal discharge and Horner's syndrome developed. Radiographs of the chest were unremarkable. He was treated with amoxicillin 2/5/22. The sneezing and nasal discharge resolved. There is a history of recurrent episodes of sneezing and watery nasal discharge (possible Herpes). Two days ago, he became anorexic and wheezing became worse. He acts like he wants to eat but doesn't eat well unless his owner adds tuna juice. Currently his wheezing has increased as well as increased respiratory effort. Two years ago Kittle he lost his hearing after both tympanic membranes were ruptured during a dental procedure (ear cleaning done). Otitis media and Horner's Syndrome followed. The Horner's syndrome resolved 2 year ago. He has been deaf since then.

Abnormal PE/Chem/CBC/UA Results: PE: **\*\*Respiratory:\*\*** Lungs auscultate clear bilaterally; mild wheezing sounds are audible; mild stridor Blood work is dated 1/28/22. CBC - PCV = 40%, WBC = 7800, neutrophils = 6084, lymphocytes = 1326, monocytes = 234. Platelets = 436,000. Chemistry - Calcium = 11.7, Amylase = 1464, Precision PSL = 54, all else normal. T4 = 2.8. Urinalysis - USG = 1.021, pH = 6.0, trace protein, WBC = 0, RBC = 0, no bacteria. Ear swab cytology (1/28/22) - TNTC cocci, 10-20 yeast/hpf AU. Both external ear canals are imaged. Ear canals are open and clean. There is no evidence of infection or inflammation. Tympanic membranes are completely missing bilaterally. Tympanic bullae are air filled and clean. The larynx is examined using a 2.7 mm 0-degree scope under light sedation and IV Dopram. Arytenoid cartilages adduct during inspiration and then relax during expiration consistent with laryngeal paralysis. The left side is worse than the right.

**COMPUTED TOMOGRAPHY OF THE SKULL**

A high resolution pre- and post-contrast CT study of the skull is provided for review.

**HOSPITAL NAME COMPUTED TOMOGRAPHIC FINDINGS**

VetMed Consultants The tooth elements 106&206 are absent.

**REFERRING VET** The nasal cavity presents the expected aerated spaces between thin & even conchae and turbinates with smooth mucosal lining.

Erin Johnston Both temporomandibular joints present congruent joint spaces with even subchondral bone surfaces and are considered within normal limits.

**INVOICE** 50368 Both tympanic bullae are aerated but a very small amount of soft tissue material attached to mucosal lining, the bony wall is smooth and thin. The external ear canals are within normal limits.

**DATE** 2-16-22 The brain presents no deviation from normal anatomy and symmetry. The brain parenchyma is homogeneous and within normal limits for attenuation and distribution of contrast enhancement. The ventricular system is non-dilated and symmetric.

The submandibular and medial retropharyngeal lymph nodes are prominent and elongated with a normal short-to-long-axis-ratio is < 0.5, the attenuation and contrast enhancement pattern is uniform.



**PATIENT** The right thyroid gland is prominent.

Kittle Daniel

**COMPUTED TOMOGRAPHIC DIAGNOSIS**

**SPECIES**

Feline

- Lymphadenopathy mandibular and medial retropharyngeal lymph nodes bilaterally
- Mild enlargement right thyroid gland
- Very mild otitis media
- Absent triadan 106&206

**INTERPRETATION OF THE FINDINGS & FURTHER RECOMMENDATIONS**

**BREED**

DSH

The CT study of the skull presents without abnormalities of the upper airways – there are no signs for active upper airway infection. The clinical relevance of the very mild otitis media is questionable. Given the clinical examination, the presumptive diagnosis is laryngeal paralysis.

**SEX**

CM

The prominent lymph nodes are compatible with reactive hyperplasia, possible secondary to preceding upper airway infection– recommend FNA sampling to confirm the diagnosis and rule out malignant transformation completely.

**AGE**

16 Years

The prominent right thyroid gland can indicate (non)functional hyperplasia or adenoma formation. Correlate with T4 values.

**INTERPRETED BY**

Sebastian Schaub, DVM  
Dr. med. vet. DipECVDI

**HOSPITAL NAME**

VetMed Consultants

**REFERRING VET**

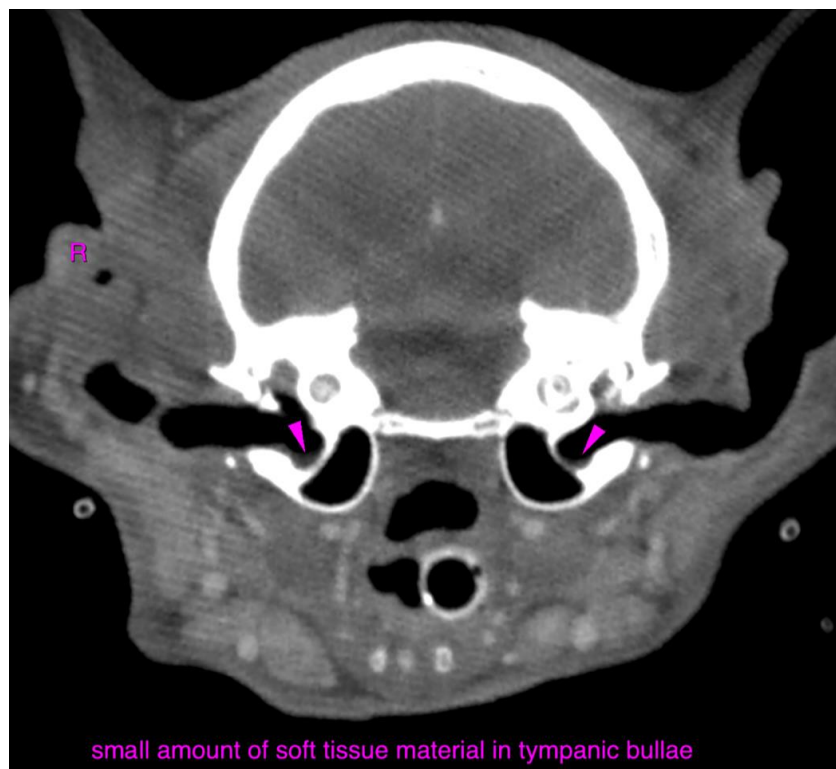
Erin Johnston

**INVOICE**

50368

**DATE**

2-16-22





**PATIENT**

Kittle Daniel

**SPECIES**

Feline

**BREED**

DSH

**SEX**

CM

**AGE**

16 Years

**INTERPRETED BY**

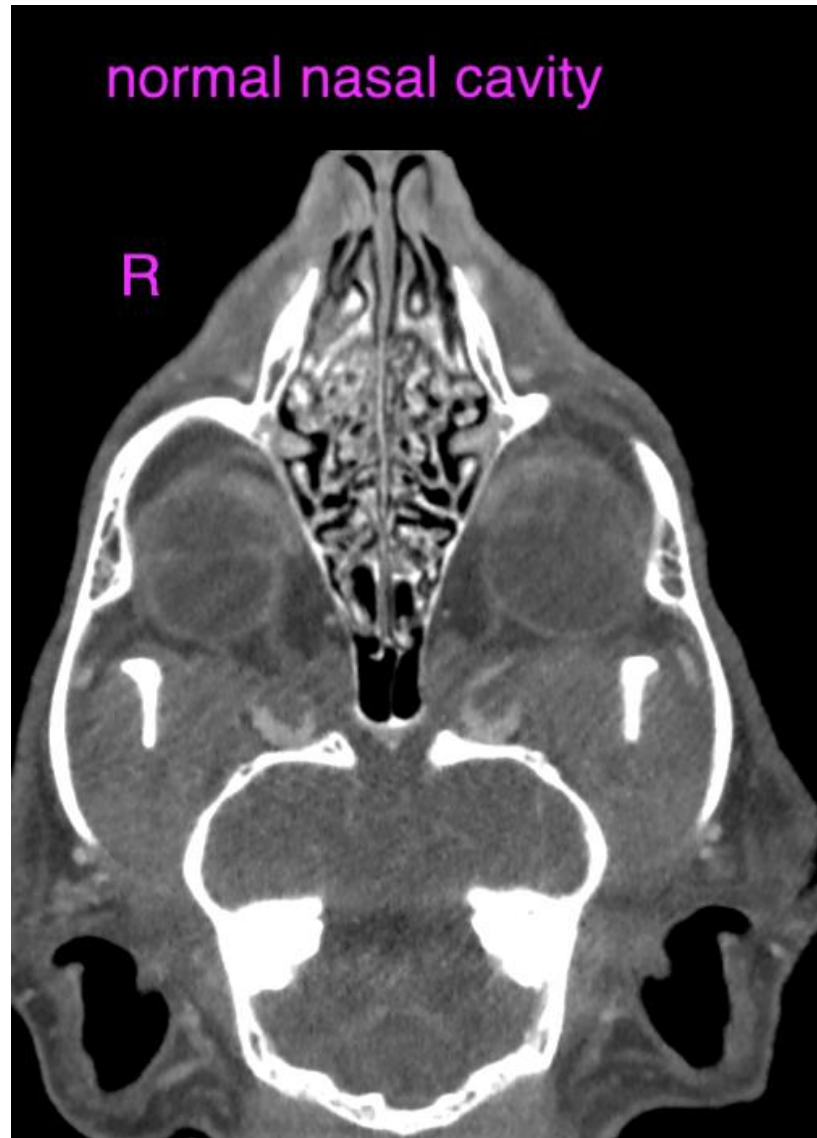Sebastian Schaub, DVM  
Dr. med. vet. DipECVDI

**HOSPITAL NAME**

VetMed Consultants

**REFERRING VET**

Erin Johnston



**INVOICE**

50368

**DATE**

2-16-22

The information and recommendations provided are based on the images presented by the referring veterinarian/sonographer. No evaluation can be communicated regarding pathology that was not visible in the image/video clips provided.

Thank you for this referral. If the clinical or image interpretation does not parallel your findings or if I can be of any further assistance please contact me.

**Sebastian Schaub**, Sebastian Schaub, DVM, Dr. med. vet. DipECVDI  
sebast.schaub@gmail.com