



**PATIENT**

Jacs Morrison

**PRESENTING CLINICAL SIGNS**

not himself , acting like he is in pain , had history of urinary stones 2 years ago but he is in urinary SO diet  
Abnormal PE/Chem/CBC/UA Results: bilateral luxating patella , BW : elevated albumen & glucose , urine is pending

**SPECIES**

Canine

**RADIOGRAPHIC STUDY OF THE LUMBAR SPINE**

A laterolaterale view of the lumbar spine is provided for review.

**BREED**

Yorkshire Terrier

**RADIOGRAPHIC FINDINGS**

The intervertebral disc space L4/L5 is moderately narrowed.

**SEX**

Male Neuter

The remainder of the osseous and soft tissue structures of the lumbar spine are within normal limits.

**RADIOGRAPHIC DIAGNOSIS**

**AGE**

8 Years

- Discopathy L4/L5

**INTERPRETATION OF THE FINDINGS & FURTHER RECOMMENDATIONS**

The narrowed intervertebral disc space indicates discopathy ± compressive myelopathy. If clinical findings is indicative for compressive myelopathy, cross-sectional imaging is warranted for further definition.

**INTERPRETED BY**

Sebastian Schaub, DVM  
Dr. med. vet. DipECVDI

**HOSPITAL NAME**

St. Catherine's Animal  
Hospital

**REFERRING VET**

Dr. Masoud

**INVOICE**

50331

**DATE**

2-16-22



**PATIENT**

Jacs Morrison

**SPECIES**

Canine

**BREED**

Yorkshire Terrier

**SEX**

Male Neuter

**AGE**

8 Years

**INTERPRETED BY**

Sebastian Schaub, DVM  
Dr. med. vet. DipECVDI

**HOSPITAL NAME**

St. Catherine's Animal  
Hospital

**REFERRING VET**

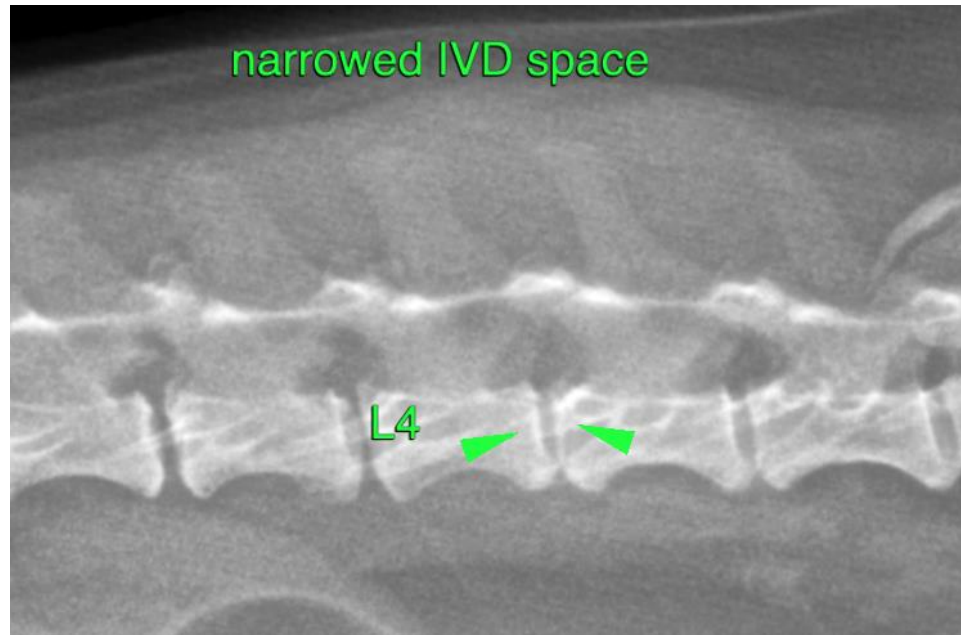
Dr. Masoud

**INVOICE**

50331

**DATE**

2-16-22



The information and recommendations provided are based on the images presented by the referring veterinarian/sonographer. No evaluation can be communicated regarding pathology that was not visible in the image/video clips provided.

Thank you for this referral. If the clinical or image interpretation does not parallel your findings or if I can be of any further assistance please contact me.

**Sebastian Schaub**, Sebastian Schaub, DVM, Dr. med. vet. DipECVDI  
sebast.schaub@gmail.com