



**PATIENT PRESENTING CLINICAL SIGNS**

**PATIENT** Google Courchesne  
**SPECIES** Canine  
**BREED** Pug  
**SEX** SF  
**AGE** 9 Years

9 year old FS Pug, 21 month history progressive paraparesis. 3 months ago acutely became painful and slightly more ataxic. improved with rest. now slow progressive paraparesis and pelvic limb ataxia that is left lateralizing and non-painful. Left mammary tumour biopsy in 2020 -: Mammary lobular hyperplasia with corpora amylacea  
 Abnormal PE/Chem/CBC/UA Results: Mentation: Bright, alert and responsive. Cranial nerve exam: No deficits noted. Gait/posture: Ambulatory with moderate paraparesis and moderate proprioceptive ataxia of pelvic limbs lateralizing to the left. Occasional erratic paw placement in the left pelvic limb with the sinking of the pelvis to the left during ambulation. Low tail carriage  
 Postural reactions: Proprioceptive positioning and hopping were moderately delayed in the left pelvic limb and mildly delayed in the right pelvic limb and normal in thoracic limbs. Spinal reflexes: Cutaneous trunci absent caudal to T13/L1 bilaterally. Mildly decreased withdrawal reflex of the left pelvic limb. Sensory/nociception: No hyperesthesia elicited with palpation along the thoracolumbar vertebral column. Assessment: Non-painful left lateralizing paraparesis and pelvic limb ataxia. CBC, Biochem - Mildly elevated urea 10.2 mmol/L (2.5 - 9.6) and ALT 256 U/L (10 - 125)

**MAGNETIC RESONANCE IMAGING OF THE THORACIC & LUMBAR SPINE**

T2&T1 (DIXON) weighted pre- and post-gadolinium sequences in multiple imaging planes are provided for review.

**MAGNETIC RESONANCE IMAGING FINDINGS**

THE LAST RIB BEARING VERTEBRA IS COUNTED AS T12.

The intervertebral discs T11/T12 and T12/T13 are mild to moderately protruding into the vertebral canal, distorting the ventral epidural and subarachnoidal space.

The spinal cord level T6 to TT11 presents a diffuse hyperintense signal in the fluid sensitive sequences. Level with the intervertebral disc space T11/T12, in the left dorsolateral aspect, a moderate teardrop shaped widening of the subarachnoidal space is visible, distorting the spinal cord at the same level.

Multiple intervertebral discs of the thoracic and lumbar spine present a mild to moderate loss of the in fluid sensitive sequences hyperintense signal of the nucleus pulposus.

Post contrast administration no pathologic distribution of contrast enhancement is seen.

**MAGNETIC RESONANCE IMAGING DIAGNOSIS**

- Only 12 thoracic vertebra are present!
- Subarachnoidal diverticulum T11/T12, left dorsal aspect
- Mild to moderate intervertebral disc protrusion T11/T12 and T12/L1 with possible dynamic spinal cord compression
- Secondary intramedullary edema and dilation of the central canal of the spinal cord cranial to the subarachnoidal diverticulum
- Multifocal degenerative disc disease along the thoracic and lumbar spine

**INTERPRETED BY**

Sebastian Schaub, DVM  
 Dr. med. vet. DipECVDI

**HOSPITAL NAME**

Animal Health  
 Partners

**REFERRING VET**

Dr. Little

**INVOICE**

50335

**DATE**

2-16-22



**PATIENT**

Google Courchesne

**SPECIES**

Canine

**BREED**

Pug

**SEX**

SF

**AGE**

9 Years

**INTERPRETED BY**

Sebastian Schaub, DVM  
Dr. med. vet. DipECVDI

**HOSPITAL NAME**

Animal Health  
Partners

**REFERRING VET**

Dr. Little

**INVOICE**

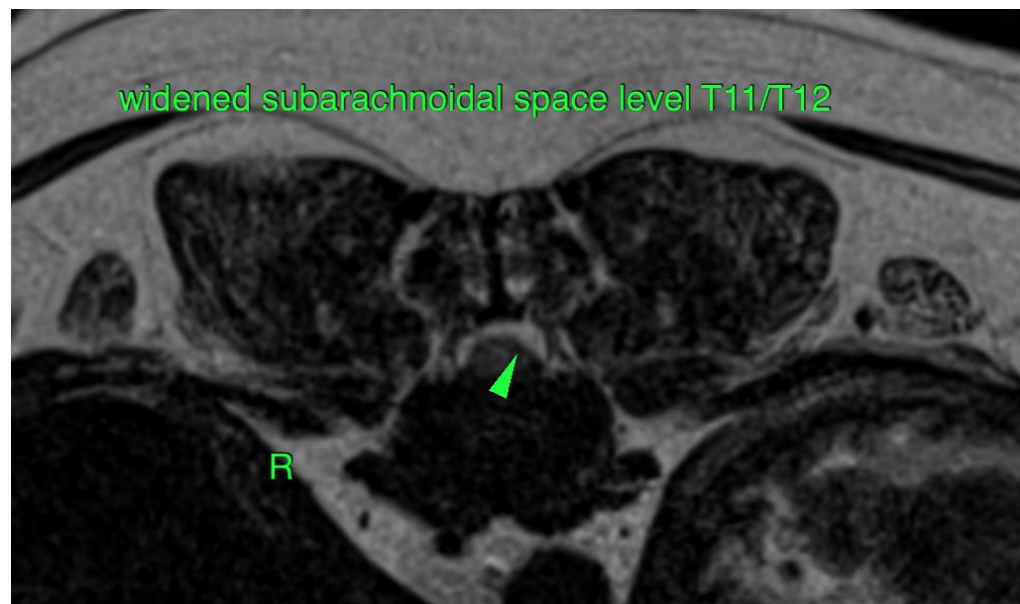
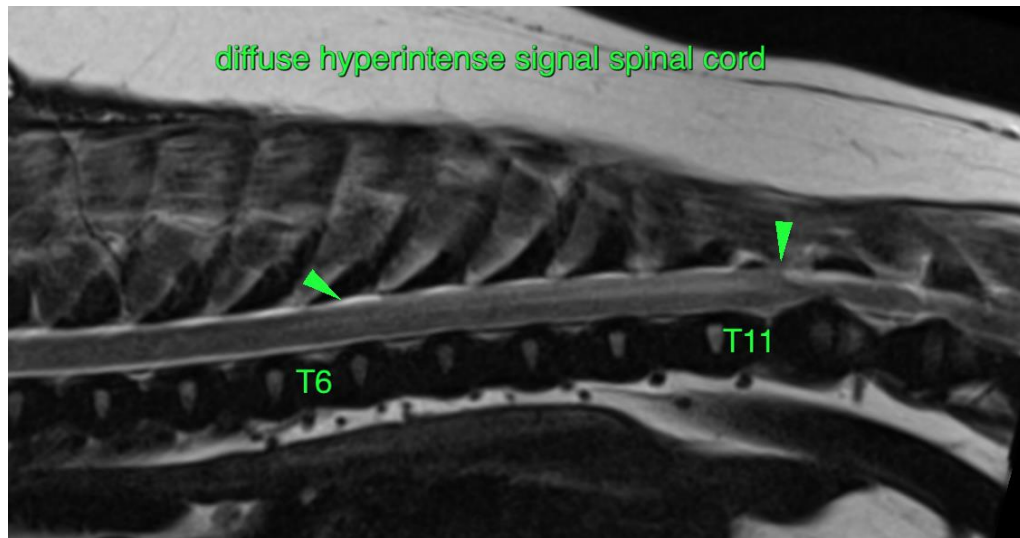
50335

**DATE**

2-16-22

**INTERPRETATION OF THE FINDINGS & FURTHER RECOMMENDATIONS**

The findings are consistent with a subarachnoid diverticulum level T11/T12 (left dorsolateral aspect) with secondary compression of the spinal cord – the finding is a plausible explanation for the described clinical signs. Both acquired (e.g. trauma, inflammation) as well as congenital malformations of the subarachnoid space – considered less likely due to the age of the patient – can be the cause for diverticulum formation. Marsupialization of the subarachnoid diverticulum/pseudocyst can be considered as potential treatment option.





**PATIENT**

Google Courchesne

The information and recommendations provided are based on the images presented by the referring veterinarian/sonographer. No evaluation can be communicated regarding pathology that was not visible in the image/video clips provided.

**SPECIES**

Canine

Thank you for this referral. If the clinical or image interpretation does not parallel your findings or if I can be of any further assistance please contact me.

**BREED**

Pug

**Sebastian Schaub**, Sebastian Schaub, DVM, Dr. med. vet. DipECVDI  
sebast.schaub@gmail.com

**SEX**

SF

**AGE**

9 Years

**INTERPRETED BY**

Sebastian Schaub, DVM  
Dr. med. vet. DipECVDI

**HOSPITAL NAME**

Animal Health  
Partners

**REFERRING VET**

Dr. Little

**INVOICE**

50335

**DATE**

2-16-22