



PATIENT

Diaz Morlacchetti

PRESENTING CLINICAL SIGNS

Vomiting several times and diarrhea with blood , not eating or drinking for 2 days.
Abnormal PE/Chem/CBC/UA Results: moderate abdominal discomfort , BW showed dehydration sever elevation of CPLI , rest WNL

SPECIES

Canine

RADIOGRAPHIC FINDINGS

Abdomen

BREED

Labrador Retriever
Mix

The surrounding bony structures are within normal limits.

No abnormalities of the extraabdominal soft tissues are noted. The abdominal wall is smooth and thin.

The serosal detail is maintained throughout the peritoneal and retroperitoneal space.

SEX

Male Neuter

The liver is appropriate in position, size and presents uniform opacity.

The splenic head is in the anticipated position and within normal limits for size and opacity. The splenic body and tail are considered normal for position, size, shape and opacity.

AGE

22 Months

Both kidneys are seen and present with normal size, shape, delineation and opacity. The urinary bladder is in its anticipated position. No radiopaque calculi are empty.

INTERPRETED BY

Sebastian Schaub, DVM
Dr. med. vet. DipECVDI

The small intestinal loops are of even diameter and non-dilated, a small amount of gas is seen within the small intestinal loops and considered within normal limits.

The colon is seen in the expected position and empty but a mild to moderate amount of gas. The cecum is moderately distended by fluid and gas.

HOSPITAL NAME

St. Catherine's Animal
Hospital

RADIOGRAPHIC DIAGNOSIS

- Empty gastrointestinal tract but mild fluid filled stomach and cecum

INTERPRETATION OF THE FINDINGS & FURTHER RECOMMENDATIONS

REFERRING VET

Dr. Masoud

The empty gastrointestinal tract with the given history is suggestive for underlying gastroenteritis. There is no evidence of radiopaque foreign material or signs for gastrointestinal mechanical obstruction. Recommend empirical management. If clinical signs are refractory to therapy, recommend follow up radiographs or a complete abdominal ultrasound examination; in some cases, a high ileus may lack classical radiographic signs of mechanical obstruction.

INVOICE

50354

DATE

2-16-22



PATIENT

Diaz Morlacchetti

SPECIES

Canine

BREED

Labrador Retriever
Mix

SEX

Male Neuter

AGE

22 Months

INTERPRETED BY

Sebastian Schaub, DVM
Dr. med. vet. DipECVDI

HOSPITAL NAME

St. Catherine's Animal
Hospital

REFERRING VET

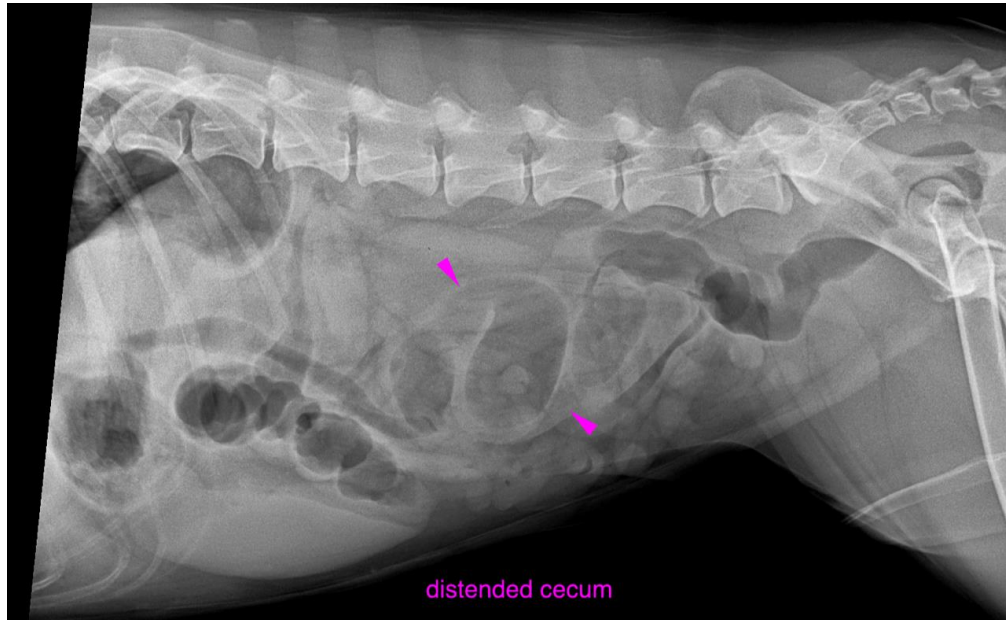
Dr. Masoud

INVOICE

50354

DATE

2-16-22



The information and recommendations provided are based on the images presented by the referring veterinarian/sonographer. No evaluation can be communicated regarding pathology that was not visible in the image/video clips provided.

Thank you for this referral. If the clinical or image interpretation does not parallel your findings or if I can be of any further assistance please contact me.

Sebastian Schaub, Sebastian Schaub, DVM, Dr. med. vet. DipECVDI
sebast.schaub@gmail.com