



PATIENT

Charleigh Blackwell

PRESENTING CLINICAL SIGNS

6 yo FS Golden Retriever. Recurrent epistaxis from left nares numerous times in January 2022. Normal clotting times and CBC parameters. Epistaxis has since resolved - none in the past 3 weeks. No nasal discharge. Dog is outdoors and often digs in the ground. Otherwise clinically normal.

SPECIES

Canine

Abnormal PE/Chem/CBC/UA Results: Normal CBC. Chemistry. Left sided mandibular lymphadenopathy, facial examination normal.

BREED

Golden Retriever

COMPUTED TOMOGRAPHY OF THE SKULL

A high resolution pre- and post-contrast CT study of the skull in a bone and soft tissue reconstruction is provided for review.

COMPUTED TOMOGRAPHIC FINDINGS

SEX

FS

The pictured parts of the dentition are complete and unremarkable in all jaw quadrants.

AGE

6 Years

The nasal cavity presents the expected aerated spaces between thin & even conchae and turbinates with smooth mucosal lining. In the caudal aspect of the right maxillary recess, a small convex shaped swelling of the mucosal lining is present.

Both temporomandibular joints present congruent joint spaces with even subchondral bone surfaces and are considered within normal limits.

INTERPRETED BY

Sebastian Schaub, DVM
Dr. med. vet. DipECVDI

Both tympanic bullae are aerated, the mucosal lining is not seen, the bony wall is smooth and thin. The external ear canals are within normal limits.

The brain presents no deviation from normal anatomy and symmetry. The brain parenchyma is homogeneous and within normal limits for attenuation and distribution of contrast enhancement. The ventricular system is non-dilated and symmetric.

HOSPITAL NAME

Animal Health
Partners

The lateral of the left mandibular lymph nodes is moderately enlarged, rounded, uniform soft tissue attenuating and presents a mild heterogeneous contrast enhancement pattern.

COMPUTED TOMOGRAPHIC DIAGNOSIS

REFERRING VET

Dr. Gold

- Lymphadenopathy left mandibular lymph node
- Small mucosal swelling right nasal maxillary recess – otherwise normal nasal cavity

INTERPRETATION OF THE FINDINGS & FURTHER RECOMMENDATIONS

INVOICE

50340

The enlarged left mandibular lymph node is equivocal for reactive hyperplasia/lymphadenitis or malignant transformation. Recommend FNA sampling for further definition.

DATE

2-16-22

The nasal cavity presents without abnormalities, but the focal mucosal swelling – most consistent with focal mucosal hyperplasia. There are no signs for malignant transformation. Possible causes for epistaxis include immune mediated disease, non-specific rhinitis (e.g. lymphocytic plasmocytic), hyperviscosity syndrome (e.g. Leishmaniosis), other causes for coagulopathy or systemic hypertension.



PATIENT

Charleigh Blackwell

SPECIES

Canine

BREED

Golden Retriever

SEX

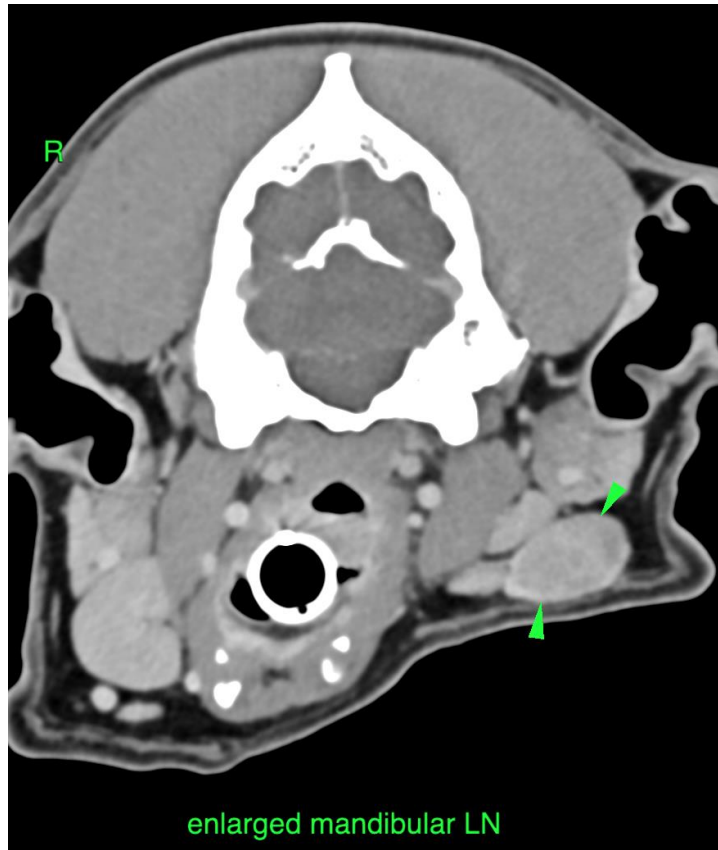
FS

AGE

6 Years

INTERPRETED BY

Sebastian Schaub, DVM
Dr. med. vet. DipECVDI



HOSPITAL NAME

Animal Health
Partners

REFERRING VET

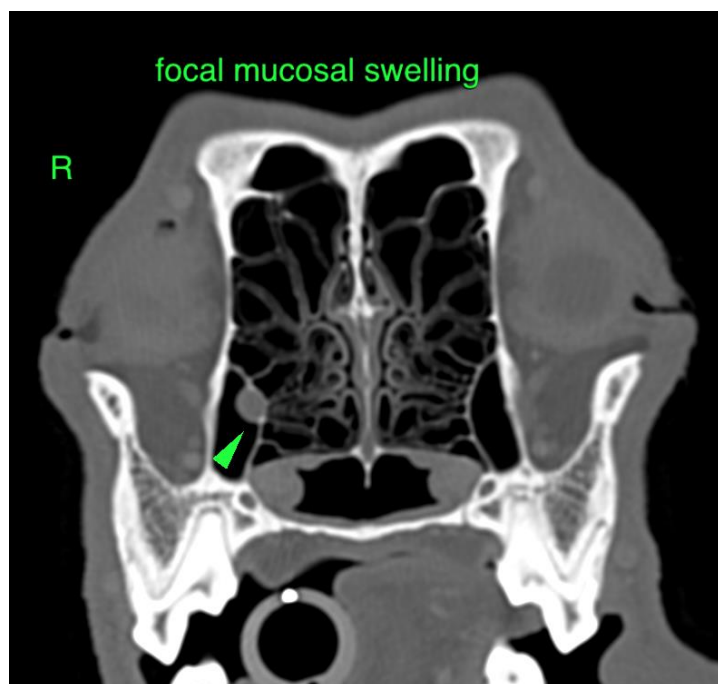
Dr. Gold

INVOICE

50340

DATE

2-16-22





PATIENT

Charleigh Blackwell

The information and recommendations provided are based on the images presented by the referring veterinarian/sonographer. No evaluation can be communicated regarding pathology that was not visible in the image/video clips provided.

SPECIES

Canine

Thank you for this referral. If the clinical or image interpretation does not parallel your findings or if I can be of any further assistance please contact me.

Sebastian Schaub, Sebastian Schaub, DVM, Dr. med. vet. DipECVDI
sebast.schaub@gmail.com

BREED

Golden Retriever

SEX

FS

AGE

6 Years

INTERPRETED BY

Sebastian Schaub, DVM
Dr. med. vet. DipECVDI

HOSPITAL NAME

Animal Health
Partners

REFERRING VET

Dr. Gold

INVOICE

50340

DATE

2-16-22