



PATIENT PRESENTING CLINICAL SIGNS

Molly Tyer Pt has hx of left stifle TPLO. O noted pt starting to limp on rt stifle 4-5 days ago. Drawer sign and toe touching lameness on rt hind.

SPECIES RADIOGRAPHIC STUDY OF THE RIGHT STIFLE JOINT

Canine Radiographs of the right stifle joint in two imaging planes are provided for review.

BREED RADIOGRAPHIC FINDINGS

Goldendoodle The volume of the right thigh musculature is mildly decreased.

The periarticular bones of the right stifle joint present mild osteophyte new bone formation and a moderate intracapsular soft tissue swelling of the left stifle joint is appreciated. The soft tissue shadow of the right popliteal lymph node is prominent.

SEX The left stifle joint is included in a craniocaudal projection. The periarticular bones of the left stifle joint present moderate osteophyte new bone formation. A metal opaque surgical clamp is superimposed on the left lateral femoral condyle.

SF

RADIOGRAPHIC DIAGNOSIS

- Mild degenerative osteoarthritis right stifle joint
- Mild articular swelling right stifle joint
- Disuse atrophy musculature right hind limb
- History of surgical management of cranial cruciate ligament pathology left stifle joint
- Moderate degenerative osteoarthritis left stifle joint

AGE

11 Years

INTERPRETED BY

Sebastian Schaub, DVM
Dr. med. vet. DipECVDI

INTERPRETATION OF THE FINDINGS & FURTHER RECOMMENDATIONS

The radiographic study is consistent with chronic degenerative osteoarthritis with concomitant joint effusion of the right stifle joint. The most-likely underlying cause is (partial) rupture of the cranial cruciate ligament with or without meniscal disease.

HOSPITAL NAME

The Pet Hospital of
Stratford

A positive drawer sign or tibial compression test under general anesthesia can be used to confirm the diagnosis.

REFERRING VET

Dr. Claudia Giuliani

INVOICE

56781

DATE

2-15-23



PATIENT

Molly Tyer

SPECIES

Canine

BREED

Goldendoodle

SEX

SF

AGE

11 Years

INTERPRETED BY

Sebastian Schaub, DVM
Dr. med. vet. DipECVDI

HOSPITAL NAME

The Pet Hospital of
Stratford

REFERRING VET

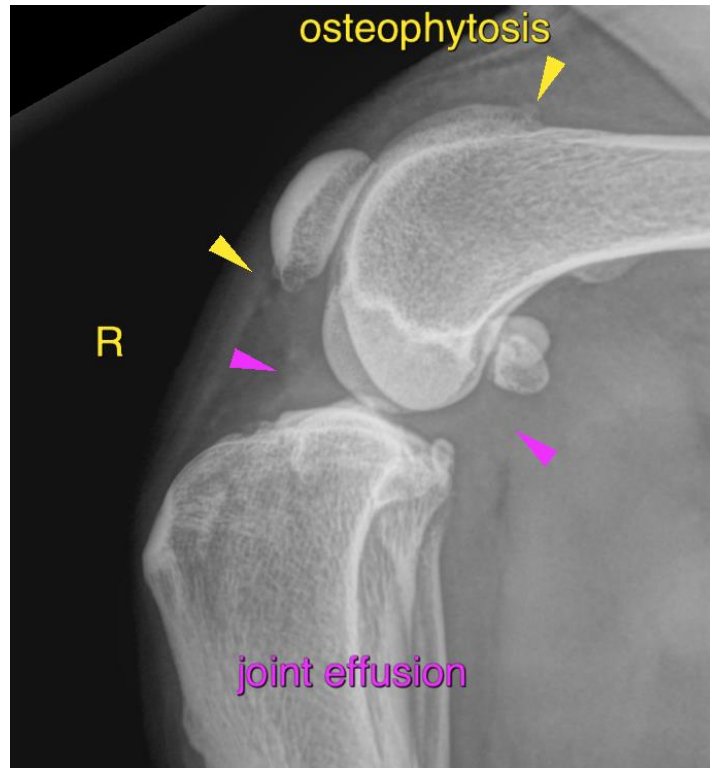
Dr. Claudia Giuliani

INVOICE

56781

DATE

2-15-23



The information and recommendations provided are based on the images presented by the referring veterinarian/sonographer. No evaluation can be communicated regarding pathology that was not visible in the image/video clips provided.

Thank you for this referral. If the clinical or image interpretation does not parallel your findings or if I can be of any further assistance please contact me.

Sebastian Schaub, Sebastian Schaub, DVM, Dr. med. vet. DipECVDI
sebast.schaub@gmail.com