



PATIENT

Nyoni Wildi

PRESENTING CLINICAL SIGNS

History of generalized seizures starting last July that are increasing in frequency. Normal mentation between seizures.
 Abnormal PE/Chem/CBC/UA Results: Normal neurological examination and blood work. Localized to thalamocortex. Cerebral spinal fluid analysis - normal

SPECIES

Canine

MAGNETIC RESONANCE IMAGING OF THE SKULL

T2 weighted, FLAIR, diffusion weighted, SWI, T1 pre- and post-gadolinium sequence in multiple imaging planes are provided for review.

BREED

Hungarian Vizsla

MAGNETIC RESONANCE IMAGING FINDINGS

The brain presents the expected anatomy and bilateral symmetry with normal signal intensity and contrast enhancement. The corpus callosum is visualized and the overall height of the corpus callosum is decreased, most accentuated level with the splenium. There is no evidence of abnormal meningeal enhancement.

SEX

SF

The ventricular system presents the expected dimensions, morphology and the CSF signal is within normal limits in all sequences.

AGE

1 Year

The tympanic bullae are aerated, and the bony lining is thin.

INTERPRETED BY

Sebastian Schaub, DVM
 Dr. med. vet. DipECVDI

Surrounding soft tissue structures in the head region are within normal limits.

MAGNETIC RESONANCE IMAGING DIAGNOSIS

- Decreased volume of the corpus callosum

HOSPITAL NAME

Animal Health Partners

INTERPRETATION OF THE FINDINGS & FURTHER RECOMMENDATIONS

The MRI study is suggestive for hypoplasia of the corpus callosum which can be associated with increased risk for seizure activity. Hyponatremia in combination with hypodipsia/adipsia is a common concurrent clinical sign in cases of corpus callosum abnormalities.

REFERRING VET

Dr. Little

To confirm diagnosis of underlying corpus callosum abnormality, diffusion tensor imaging can be used to check for presence of Probst bundles and lack of axonal bundles crossing the cerebral hemispheres by the corpus callosum.

INVOICE

50297

DATE

2-15-22



PATIENT

Nyoni Wildi

SPECIES

Canine

BREED

Hungarian Vizsla

SEX

SF

AGE

1 Year

INTERPRETED BY

Sebastian Schaub, DVM
Dr. med. vet. DipECVDI

HOSPITAL NAME

Animal Health
Partners

REFERRING VET

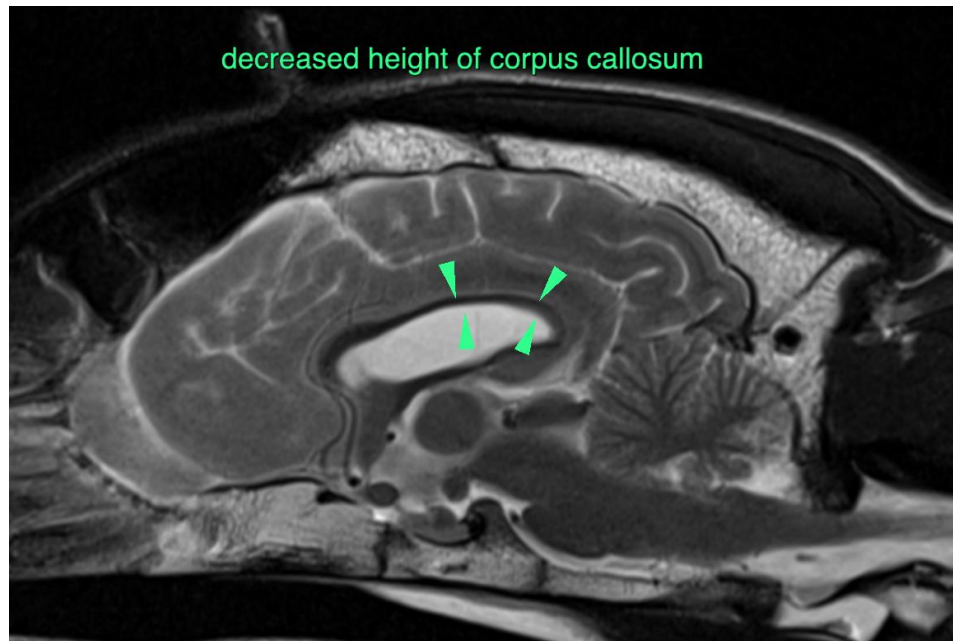
Dr. Little

INVOICE

50297

DATE

2-15-22



The information and recommendations provided are based on the images presented by the referring veterinarian/sonographer. No evaluation can be communicated regarding pathology that was not visible in the image/video clips provided.

Thank you for this referral. If the clinical or image interpretation does not parallel your findings or if I can be of any further assistance please contact me.

Sebastian Schaub, Sebastian Schaub, DVM, Dr. med. vet. DipECVDI
sebast.schaub@gmail.com