



PATIENT PRESENTING CLINICAL SIGNS

Maple Wolff
SPECIES Canine
BREED Labrador Retriever
SEX FS
AGE 1 Year, 2 Months

Maple presented for evaluation of a right thoracic limb lameness. Maple is now rested; only allowed out in backyard. Normal EDUD; No VDSC. Maple was initially noticed to be limping on the right thoracic leg approximately 1.5 months ago. She starts limping when plays or jumps off bed. The cause of the lameness is not known yet, suspecting developmental disease given age and elbow effusion. Maple has had a previous history of ear infections, OTE (AD) and spay (Dec 2021). Maple is currently eating RC Labrador adult, with no history of allergies. Maple is UTD on vaccines.

Abnormal PE/Chem/CBC/UA Results: forelimbs: Moderate shoulder muscle atrophy. No digital crepitus or pain. No carpal effusion, normal range of motion. Full range of motion of Lt elbow with mild discomfort on full flexion, decreased range of motion of Rt elbow especially in flexion with marked discomfort. No apparent pain on coronoid palpation -- unsure due to patient's stoic demeanor. No pain on shoulder extension or flexion.

COMPUTED TOMOGRAPHY OF THE FRONT LIMBS

A high resolution plain CT study of the front limbs in a soft tissue and bone reconstruction is provided for review.

COMPUTED TOMOGRAPHIC FINDINGS

Both elbow joints present a moderate periarticular soft tissue swelling.

The periarticular osseous structures of the elbow joints present mild (L) to marked (R) osteophyte new bone formation. At the cranial aspect of the left medial coronoid process, three isolated mineral attenuating bodies are seen, measuring between 0.5 to 4 mm in size. At the cranial aspect of the medial coronoid process of the right elbow joint, a large isolated fragment, measuring 7.1 x 4.6 x 4.8 mm in size. The subchondral bone of the medial condyle of the right humerus opposing the coronoid process is mildly irregular. A mild incongruity of the right elbow joint is noted.

COMPUTED TOMOGRAPHIC DIAGNOSIS

- Fragmented medial coronoid process (FCP) elbow joints bilaterally
- Degenerative osteoarthritis elbow joints bilaterally, R>>L
- Contact lesion medial humeral condyle right elbow joint
- Incongruity right elbow joint
- Articular swelling elbow joints bilaterally

INTERPRETATION OF THE FINDINGS & FURTHER RECOMMENDATIONS

The findings are consistent with mild to moderate chronic degenerative joint disease of both elbow joints, R>>L, due to a fragmented medial coronoid process. Secondary contact lesion right medial humeral condyle.

Arthroscopy is recommended to revise the elbow joints and remove the fragments of the medial coronoid process and prevent further damage.

INVOICE

50292

DATE

2-15-22

INTERPRETED BY

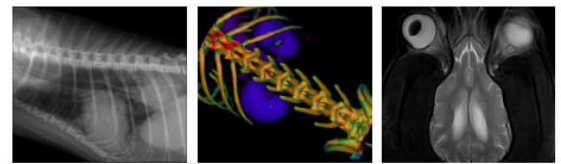
Sebastian Schaub, DVM
 Dr. med. vet. DipECVDI

HOSPITAL NAME

Animal Health
 Partners

REFERRING VET

Dr. Jeffery Biskup



PATIENT

Maple Wolff

SPECIES

Canine

BREED

Labrador Retriever

SEX

FS

AGE

1 Year, 2 Months

INTERPRETED BY

Sebastian Schaub, DVM
Dr. med. vet. DipECVDI

HOSPITAL NAME

Animal Health
Partners

REFERRING VET

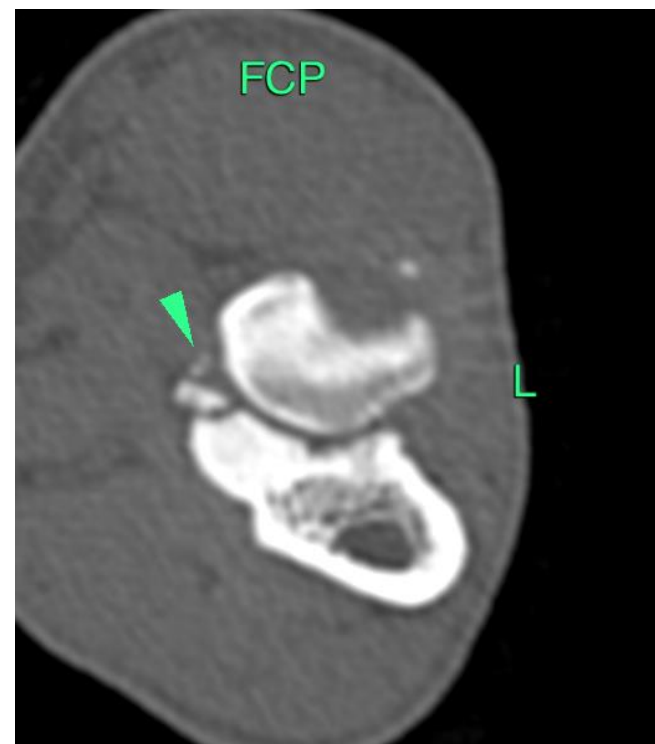
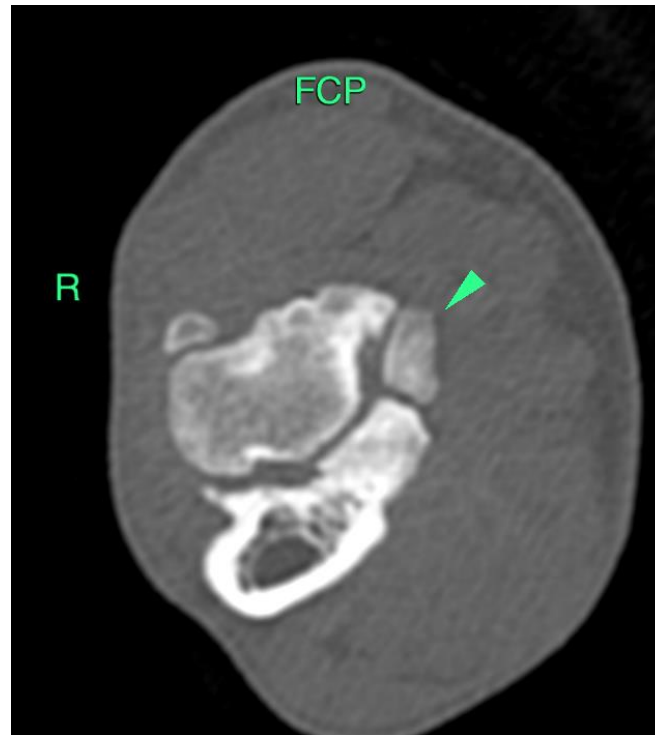
Dr. Jeffery Biskup

INVOICE

50292

DATE

2-15-22





PATIENT

Maple Wolff

SPECIES

Canine

BREED

Labrador Retriever

SEX

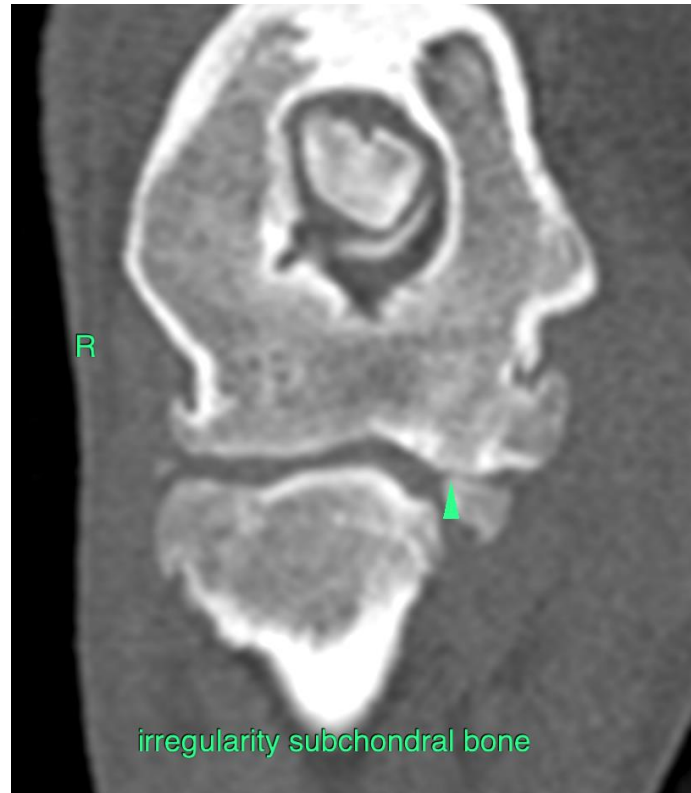FS

AGE

1 Year, 2 Months

INTERPRETED BY

Sebastian Schaub, DVM
Dr. med. vet. DipECVDI



HOSPITAL NAME

Animal Health
Partners

REFERRING VET

Dr. Jeffery Biskup

INVOICE

50292

DATE

2-15-22

The information and recommendations provided are based on the images presented by the referring veterinarian/sonographer. No evaluation can be communicated regarding pathology that was not visible in the image/video clips provided.

Thank you for this referral. If the clinical or image interpretation does not parallel your findings or if I can be of any further assistance please contact me.

Sebastian Schaub, Sebastian Schaub, DVM, Dr. med. vet. DipECVDI
sebast.schaub@gmail.com