



PATIENT PRESENTING CLINICAL SIGNS

Maggie Ingleby several month history of sneezing, stertorous breathing/congestion that recently progressed to unilateral bloody nasal discharge.

SPECIES COMPUTED TOMOGRAPHY OF THE SKULL, THORAX AND ABDOMEN

Feline A pre- and post-contrast CT study of the skull, thorax and abdomen in a bone , lung and soft tissue reconstruction are provided for review.

BREED COMPUTED TOMOGRAPHIC FINDINGS

DSH Skull

Multiple teeth are absent. The crown of triadan 104 is fractured and extensive resorption of the tooth root of triadan 104 is noted. Advanced resorption of the crown of triadan 407 is absent.

SEX

FS The right nasal cavity is filled with soft tissue attenuating and moderate contrast enhancing material. In the caudal aspect, the nasal mass is protruding into the left nasal cavity and occupying the lumen of the choana. The perpendicular plate of the right palatine bone presents with moth eaten osteolytic lesions and the nasal mass is bulging mildly into the right orbit. The cribriform plate presents a small zone of osteolysis in the ventral aspect and the nasal contrast enhancing soft tissue material is bulging mildly into the rostral cranial fossa.

AGE

15 Years

INTERPRETED BY

Sebastian Schaub, DVM
Dr. med. vet. DipECVDI

Both temporomandibular joints present congruent joint spaces with even subchondral bone surfaces and are considered within normal limits.

Both tympanic bullae are aerated, the mucosal lining is not seen, the bony wall is smooth and thin. The external ear canals are within normal limits.

HOSPITAL NAME

Animal Health Partners

The brain presents no deviation from normal anatomy and symmetry. The brain parenchyma is homogeneous and within normal limits for attenuation and distribution of contrast enhancement. The ventricular system is non-dilated and symmetric.

The submandibular and medial retropharyngeal lymph nodes are small and elongated with a normal short-to-long-axis-ratio is < 0.5, the attenuation and contrast enhancement pattern is uniform.

REFERRING VET

Dr. Westgarth

The right thyroid gland is moderately enlarged, measuring 6.9 x 5.1 x 15.1 mm in size.

Thorax

INVOICE

50318

The bony and surrounding soft tissue structures are within normal limits.

The sternal, cranial mediastinal and tracheobronchial lymph nodes are small elongated with a normal short-to-long-axis-ratio is < 0.5, the attenuation and contrast enhancement pattern is uniform and considered within normal limits.

DATE

2-15-22

The cardiovascular structures including the pulmonary vasculature are within normal limits.

The bronchial tree presents with regular branching and tapers uniformly towards the periphery



PATIENT

Maggie Ingleby

as expected, the bronchial walls are thin and smooth. The bronchus-to-artery ratio is within normal limits.

The lung parenchyma presents the expected architecture and attenuation behavior, but a small zone of dystelectasis of the right middle lung lobe – presenting as plate-like atelectasis.

SPECIES

Feline

Small incidental gas pockets are seen within the esophageal lumen, there is no evidence of abnormal dilation.

Abdomen

BREED

DSH

The serosal fat presents normal attenuation behavior. There is no evidence of peritoneal effusion or peritonitis.

SEX

FS

Both kidneys present within normal limits for size, shape and organ architecture. After contrast administration a bilaterally symmetric and uniform nephro- and pyelogram is noted.

The adrenal glands are within normal limits for size, shape and organ architecture.

AGE

15 Years

The spleen presents with normal shape, even surface, uniformly attenuating parenchyma and homogeneous contrast enhancement, unremarkable.

Originating either from the quadrate or right medial liver lobe, a mild heterogeneous soft tissue attenuating and heterogeneous moderate contrast enhancing bilobed mass is visible, measuring 5.0 x 3.6 x 5.5 cm in size. The mass is displacing the gallbladder dorsally and caudally. The remainder of the hepatic parenchyma are uniform soft tissue attenuating and contrast enhancing.

INTERPRETED BY

Sebastian Schaub, DVM
Dr. med. vet. DipECVDI

The pancreas is evenly contoured, the pancreatic parenchyma is homogeneous and presents uniform contrast enhancement.

HOSPITAL NAME

Animal Health
Partners

The position, delineation, wall and content of the gastrointestinal tract are considered within normal limits throughout.

The bony and surrounding soft tissue structures reveal no abnormalities.

COMPUTED TOMOGRAPHIC DIAGNOSIS

REFERRING VET

Dr. Westgarth

- Right sided nasal soft tissue neoplasia
- Hepatic mass with heterogeneous contrast enhancement pattern
- Nodular enlargement right thyroid gland
- Complicated dental fracture 104 with advanced tooth root resorption
- Multiple resorptive dental lesions
- No evidence of pulmonary metastatic disease

INVOICE

50318

INTERPRETATION OF THE FINDINGS & FURTHER RECOMMENDATIONS

DATE

2-15-22

The nasal mass is consistent with primary nasal neoplasia, such as lymphosarcoma, adenocarcinoma, squamous cell carcinoma, melanoma, other. The nasal mass is perforating the cranial fossa. Rhinoscopy with biopsy can be performed for further definition.

The hepatic mass is suggestive for a second neoplastic entity, such as hepatocellular carcinoma,



PATIENT

Maggie Ingleby

cholangiocellular carcinoma, neuroendocrine tumor, other. Ultrasound guided FNA sampling can be performed as minimally invasive advanced diagnostic tool. Surgical excision of the mass appears feasible, although it is in close proximity to the hepatic hilar region and 'forming' the gallbladder bed.

SPECIES

Feline

The enlarged right thyroid gland is compatible with (non) functional thyroid adenoma. Correlate with T4 values.

BREED

DSH

SEX

FS

AGE

15 Years

INTERPRETED BY

Sebastian Schaub, DVM
Dr. med. vet. DipECVDI

HOSPITAL NAME

Animal Health
Partners

REFERRING VET

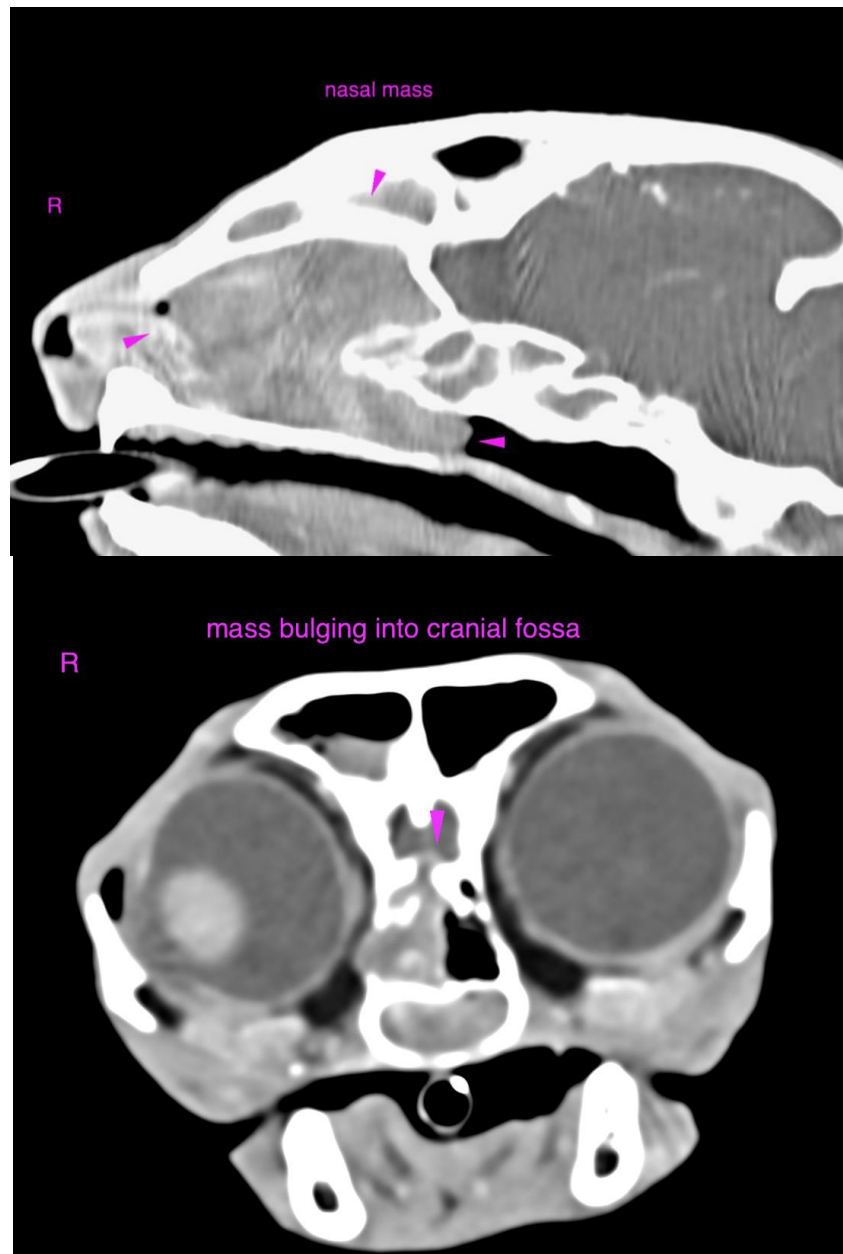Dr. Westgarth

INVOICE

50318

DATE

2-15-22





PATIENT

Maggie Ingleby

SPECIES

Feline

BREED

DSH

SEX

FS

AGE

15 Years

INTERPRETED BY

Sebastian Schaub, DVM
Dr. med. vet. DipECVDI

HOSPITAL NAME

Animal Health
Partners

REFERRING VET

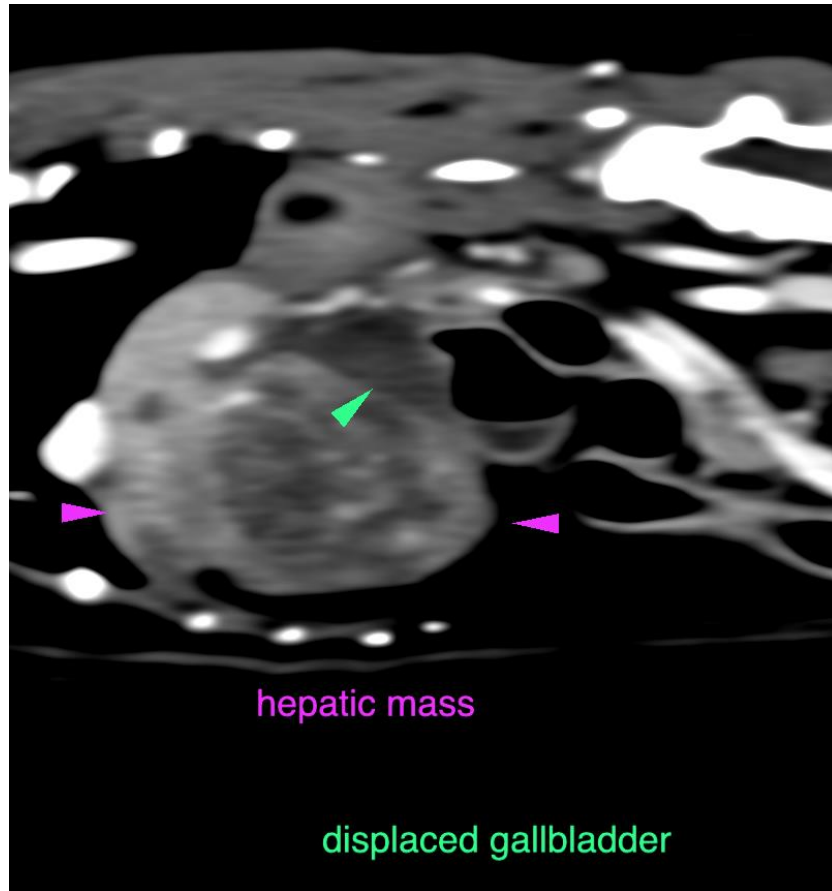
Dr. Westgarth

INVOICE

50318

DATE

2-15-22



The information and recommendations provided are based on the images presented by the referring veterinarian/sonographer. No evaluation can be communicated regarding pathology that was not visible in the image/video clips provided.

Thank you for this referral. If the clinical or image interpretation does not parallel your findings or if I can be of any further assistance please contact me.

Sebastian Schaub, Sebastian Schaub, DVM, Dr. med. vet. DipECVDI
sebast.schaub@gmail.com