



PATIENT

Kara Garvin

SPECIES

Canine

BREED

Papillon

SEX

F

AGE

3

WEIGHT

3.5

INTERPRETED BY

Sebastian Schaub, DVM
Dr. med. vet.
DipECVDI

IMAGING PERFORMED BY

Henry Xue

HOSPITAL NAME

Belconnen Veterinary
Centre

REFERRING VET

Henry Xue

INVOICE

73750

DATE

2-14-26

PRESENTING CLINICAL SIGNS

- previously dx Chiari malformation
- acute onset of seizures recently

Abnormal PE/Chem/CBC/UA Results: elevated ALT 235

COMPUTED TOMOGRAPHY OF THE ABDOMEN

A pre- and post-contrast CT study of the abdomen in a bone and soft tissue reconstruction is provided for review.

COMPUTED TOMOGRAPHIC FINDINGS

The serosal fat presents normal attenuation behavior. There is no evidence of peritoneal effusion or peritonitis.

Both kidneys present within normal limits for size, shape and organ architecture. After contrast administration, a bilaterally symmetric and uniform nephro- and pyelogram is noted.

The adrenal glands are within normal limits for size, shape and organ architecture.

Both liver and spleen present with normal shape, even surface, uniformly attenuating parenchyma and homogeneous contrast enhancement, unremarkable.

The portal vein presents a normal order of its tributary veins and intrahepatic branching. No abnormal vessel is noted inside and outside of the liver parenchyma.

The pancreas is evenly contoured; the pancreatic parenchyma is homogeneous and presents uniform contrast enhancement.

The position, delineation, wall and content of the gastrointestinal tract are considered within normal limits throughout.

The bony and surrounding soft tissue structures reveal no abnormalities.

COMPUTED TOMOGRAPHIC DIAGNOSIS

- No evidence of portosystemic shunting, neither intra- nor extrahepatic

INTERPRETATION OF THE FINDINGS & FURTHER RECOMMENDATIONS

No macroscopic vascular bypass of the liver was noted in the pre- and post-contrast studies of the abdomen. However, if the clinical signs are consistent with insufficiency of the liver primary non-cirrhotic portal hypertension (microvascular dysplasia) or other diffuse parenchymal liver disease workup should be complemented by ultrasound guided FNA sampling/TruCut biopsy or surgical liver biopsy (may have the best diagnostic yield).



PATIENT

Kara Garvin

SPECIES

Canine

BREED

Papillon

SEX

F

AGE

3

WEIGHT

3.5

INTERPRETED BY

Sebastian Schaub, DVM
Dr. med. vet.
DipECVDI

IMAGING PERFORMED BY

Henry Xue

HOSPITAL NAME

Belconnen Veterinary
Centre

REFERRING VET

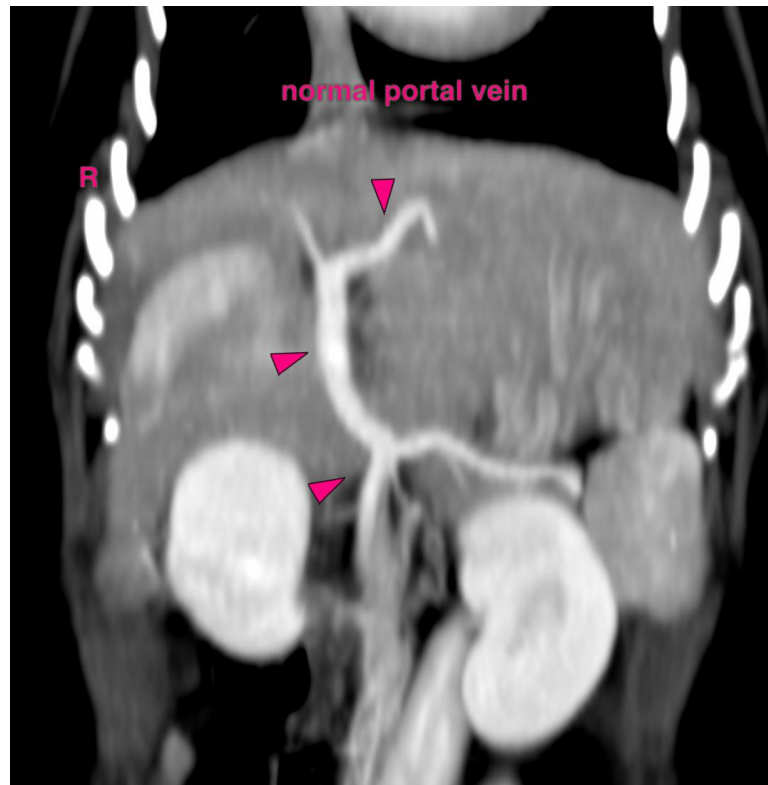
Henry Xue

INVOICE

73750

DATE

2-14-26



The information and recommendations provided are based on the images presented by the referring veterinarian/sonographer. No evaluation can be communicated regarding pathology that was not visible in the image/video clips provided.

Thank you for this referral. If the clinical or image interpretation does not parallel your findings or if I can be of any further assistance please contact me.

Sebastian Schaub, Sebastian Schaub, DVM, Dr. med. vet. DipECVDI
info@sonopath.com