



PATIENT

Truffle Rosenblatt

PRESENTING CLINICAL SIGNS

Truffle 2 y/o SF, Thursday last week v once, Sat night noticed not eating as well as usual, will eat table scraps and treat but not her normal food, pooping once a day used to be 3. No other health concerns. vomited once Saturday, unknown contents, no vomiting since, Abnormal PE/Chem/CBC/UA Results: Mentation: QAR Oral cavity: mild to minimal dental tartar. no gingivitis Bloodwork results pending

SPECIES

Canine

RADIOGRAPHIC STUDY OF THE ABDOMEN

Radiographs of the abdomen in two imaging planes are provided for review.

BREED

Cockapoo

RADIOGRAPHIC FINDINGS

The surrounding bony structures are within normal limits.

SEX

SF

No abnormalities of the extraabdominal soft tissues are noted. The abdominal wall is smooth and thin.

The serosal detail is maintained throughout the peritoneal and retroperitoneal space.

The liver is appropriate in position, size and presents uniform opacity.

AGE

2 Years, 2 Months

The splenic head is in the anticipated position and within normal limits for size and opacity. The splenic body and tail are considered normal for position, size, shape and opacity.

Both kidneys are seen and present with normal size, shape, delineation and opacity. The urinary bladder is in its anticipated position. No radiopaque calculi are noted throughout the upper and lower urinary tract.

INTERPRETED BY

Sebastian Schaub, DVM
Dr. med. vet. DipECVDI

The stomach is in its anticipated position and empty.

The small intestinal loops are of even diameter and non-dilated and present a foamy gas pattern.

The colon is seen in the expected position and contains a small amount of fecal material.

HOSPITAL NAME

DPC Veterinary
Hospital

RADIOGRAPHIC DIAGNOSIS

- Gas pattern small intestinal tract
- Empty stomach

REFERRING VET

Cepero

INTERPRETATION OF THE FINDINGS & FURTHER RECOMMENDATIONS

The gastrointestinal tract presents with a mild foamy gas pattern, possibly indicating enteritis, dysbacteriosis or parasitic infection. There is no evidence of radiopaque foreign material or signs for gastrointestinal mechanical obstruction.

INVOICE

56758

DATE

2-14-23



PATIENT

Truffle Rosenblatt

SPECIES

Canine

BREED

Cockapoo

SEX

SF

AGE

2 Years, 2 Months

INTERPRETED BY

Sebastian Schaub, DVM
Dr. med. vet. DipECVDI

HOSPITAL NAME

DPC Veterinary
Hospital

REFERRING VET

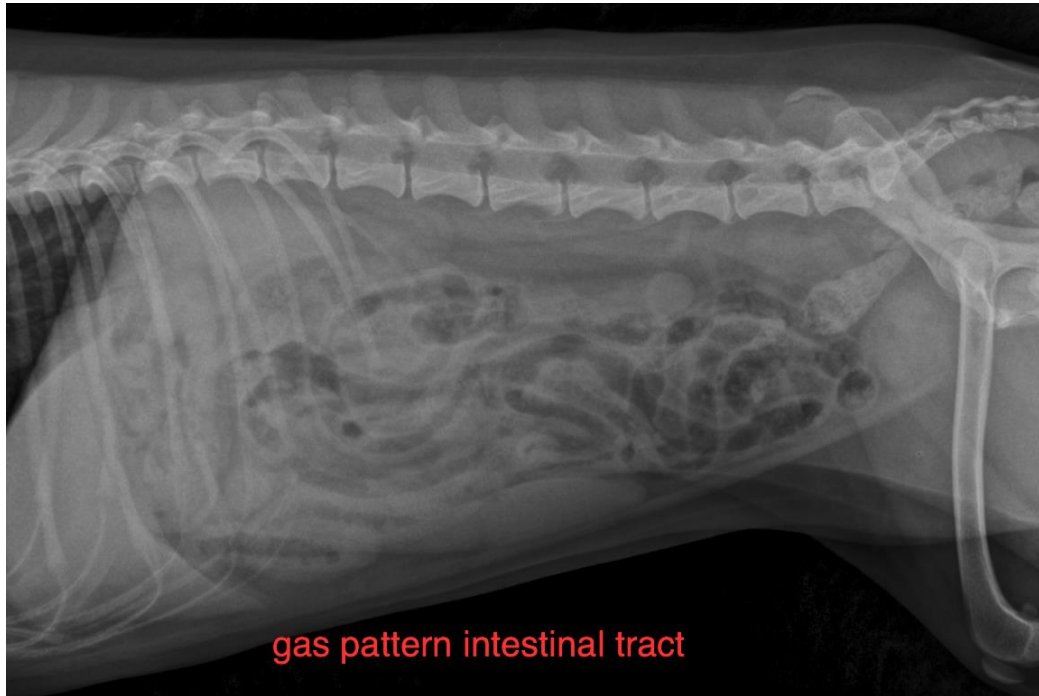
Cepero

INVOICE

56758

DATE

2-14-23



The information and recommendations provided are based on the images presented by the referring veterinarian/sonographer. No evaluation can be communicated regarding pathology that was not visible in the image/video clips provided.

Thank you for this referral. If the clinical or image interpretation does not parallel your findings or if I can be of any further assistance please contact me.

Sebastian Schaub, Sebastian Schaub, DVM, Dr. med. vet. DipECVDI
sebast.schaub@gmail.com