



PATIENT

Cabo Sundvick

PRESENTING CLINICAL SIGNS

Allison thought Cabo might have vestibular disease because he was shaky, dizzy, panting more than usual and acting disoriented. He does not want to walk down the stairs and has seems very sensitive. He had some snow on his face and Dan tried to wipe off the snow and Cabo yelped. He was off his food for a day or so but his appetite has returned. He has off and on pancreatic issues. Allison thinks he might be in pain.

SPECIES

Canine

Abnormal PE/Chem/CBC/UA Results: Abdomen - MILD TO MODERATE SUBXYPHOID TENDERNESS SCLEROSIS NORMAL FOR AGE. STAGE III TO IV DENAL DISEASE MILD TACHYCARDIA TL TENDERNESS TO DEEP PALPATION. PAIN ON EXTENSION OF CERVICAL SPINE AND ON TURN TO LEFT

BREED

Wheaten Terrier

RADIOGRAPHIC STUDY OF THE CERVICAL & THORACIC SPINE

Radiographs of the cervical & thoracic spine in two imaging planes are provided for review.

SEX

MN

RADIOGRAPHIC FINDINGS

The radiograph of the cervical spine is moderately rotated. No abnormalities of the osseous and surrounding soft tissue structures of the cervical spine are appreciated.

AGE

11 Years, 10 Months

The intervertebral disc space T12/T13 is moderately narrowed. The vertebral endplates of the thoracolumbar junction present mild spondylosis formation.

INTERPRETED BY

Sebastian Schaub, DVM
Dr. med. vet. DipECVDI

RADIOGRAPHIC DIAGNOSIS

- Discopathy T12/T13
- Normal cervical spine

HOSPITAL NAME

Elizabeth Animal
Hospital

INTERPRETATION OF THE FINDINGS & FURTHER RECOMMENDATIONS

No overt abnormalities of the cervical spine are appreciated, but there is moderate rotation and titling the of the projections of the cervical spine, limiting the diagnostic value.

The narrowed intervertebral disc space T12/T13 is suggestive for discopathy ± compressive myelopathy.

REFERRING VET

Leon Anderson, DVM

Cross-sectional imaging can be used as advanced diagnostic test, if clinical signs are refractory to empirical management by the means of rest and pain management.

INVOICE

50288

DATE

2-14-22



PATIENT

Cabo Sundvick

SPECIES

Canine

BREED

Wheaten Terrier

SEX

MN

AGE

11 Years, 10 Months

INTERPRETED BY

Sebastian Schaub, DVM
Dr. med. vet. DipECVDI

HOSPITAL NAME

Elizabeth Animal
Hospital

REFERRING VET

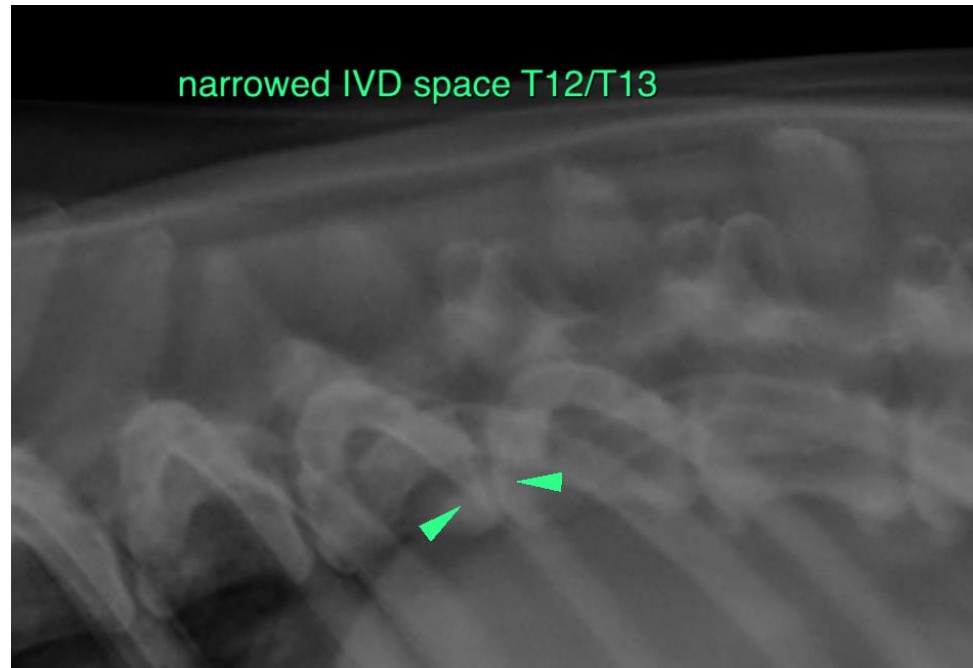
Leon Anderson, DVM

INVOICE

50288

DATE

2-14-22



The information and recommendations provided are based on the images presented by the referring veterinarian/sonographer. No evaluation can be communicated regarding pathology that was not visible in the image/video clips provided.

Thank you for this referral. If the clinical or image interpretation does not parallel your findings or if I can be of any further assistance please contact me.

Sebastian Schaub, Sebastian Schaub, DVM, Dr. med. vet. DipECVDI
sebast.schaub@gmail.com