



**PATIENT PRESENTING CLINICAL SIGNS**

Blitz Jameson R stifle luxating patella for several years which only luxates every 3 months or so Recently dog starting crying in pain when area around lower spine was pushed on.  
 Abnormal PE/Chem/CBC/UA Results: ON PE- R knee grade 2 mpl with grinding when luxated. no lameness seen. no pain on tail manipulation or manipulation of any joints. no neuro deficits

**SPECIES**

Canine

**RADIOGRAPHIC STUDY OF THE PELVIS AND STIFLE JOINTS**

A complete set of radiographs of the pelvis and stifle joints is provided for review.

**BREED**

Sheperd X

**RADIOGRAPHIC FINDINGS**

The pictured parts of the lumbar spine present without abnormalities.

**SEX**

The osseous and surrounding soft tissue structures of the pelvis are within normal limits. The joint space of the coxofemoral joints is congruent, unremarkable.

MN

The left stifle joint presents smooth osseous margins and without signs for intracapsular soft tissue swelling.

**AGE**

7 Years

The periarticular bones of the right stifle joint present moderate osteophyte new bone formation. There is a mild intracapsular soft tissue swelling of the right stifle joint, distorting the infrapatellar fat pad cranially and the fascial plane caudally.

**INTERPRETED BY**

Sebastian Schaub, DVM  
 Dr. med. vet. DipECVDI

**RADIOGRAPHIC DIAGNOSIS**

- Moderate degenerative osteoarthritis right stifle joint
- Mild articular swelling right stifle joint

**HOSPITAL NAME**

Boca Park Animal Hospital

**INTERPRETATION OF THE FINDINGS & FURTHER RECOMMENDATIONS**

The degenerative joint disease of the right stifle joint is considered as a sequela to the history of medial patellar luxation, due to the lack of clinical signs the clinical relevance is unclear.

**REFERRING VET**

Ensign

No abnormalities of the lumbar spine are appreciated, however that does not rule out possible intervertebral disc disease/degenerative lumbosacral stenosis. If there is suspicion for compressive myelopathy, cross-sectional imaging can be performed as advanced imaging modality.

**INVOICE**

50269

**DATE**

2-14-22



**PATIENT**

Blitz Jameson

**SPECIES**

Canine

**BREED**

Sheperd X

**SEX**

MN

**AGE**

7 Years

**INTERPRETED BY**

Sebastian Schaub, DVM  
Dr. med. vet. DipECVDI

**HOSPITAL NAME**

Boca Park Animal  
Hospital

**REFERRING VET**

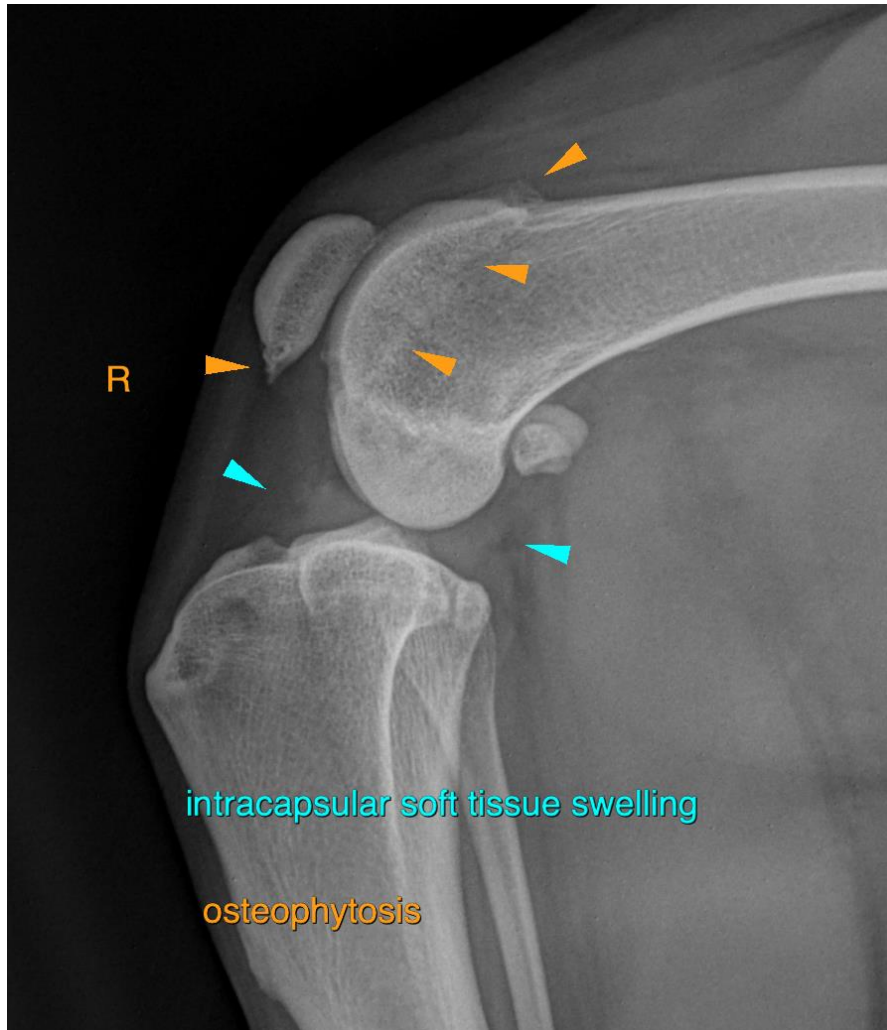
Ensign

**INVOICE**

50269

**DATE**

2-14-22



The information and recommendations provided are based on the images presented by the referring veterinarian/sonographer. No evaluation can be communicated regarding pathology that was not visible in the image/video clips provided.

Thank you for this referral. If the clinical or image interpretation does not parallel your findings or if I can be of any further assistance please contact me.

**Sebastian Schaub**, Sebastian Schaub, DVM, Dr. med. vet. DipECVDI  
sebast.schaub@gmail.com