



PATIENT PRESENTING CLINICAL SIGNS

Merlin Garnett Epitheliotropic lymphoma LEFT buccal mucosal on histopathology - met check
Abnormal PE/Chem/CBC/UA Results: cytology liver nodule pending cbc/chem pending

SPECIES COMPUTED TOMOGRAPHY OF THE THORAX AND ABDOMEN

Canine A pre- and post-contrast CT study of the abdomen and a post-contrast CT study of the thorax are provided for review.

BREED COMPUTED TOMOGRAPHIC FINDINGS

Kelpie Thorax

The bony and surrounding soft tissue structures are within normal limits.

SEX The sternal, cranial mediastinal and tracheobronchial lymph nodes are small elongated with a normal short-to-long-axis-ratio is < 0.5, the attenuation and contrast enhancement pattern is uniform and considered within normal limits.

MN The left atrium of the heart is prominent.

AGE The left principal bronchus is significantly dorsoventrally flattened. The bronchial tree presents with regular branching and tapers uniformly towards the periphery as expected, the bronchial walls are thin and smooth. The bronchus-to-artery ratio is within normal limits.

10 The lung parenchyma presents the expected architecture and attenuation behavior.

INTERPRETED BY

Sebastian Schaub, DVM
Dr. med. vet. DipECVDI

Small incidental gas pockets are seen within the esophageal lumen, there is no evidence of abnormal dilation.

Abdomen

HOSPITAL NAME

The serosal fat presents normal attenuation behavior. There is no evidence of peritoneal effusion or peritonitis.

Advanced Veterinary
Imaging

Both kidneys present within normal limits for size, shape and organ architecture. After contrast administration throughout the renal cortex bilaterally, small (<2 mm) roundish, well-defined parenchymal filling defects are noted.

REFERRING VET

Eamon The adrenal glands are within normal limits for size, shape and organ architecture.

INVOICE

56746

The spleen presents with normal shape, even surface, uniformly attenuating parenchyma and homogeneous contrast enhancement, unremarkable.

The hepatic volume is mildly increased and the caudoventral hepatic margins are mildly rounded. The hepatic parenchyma has a mild heterogeneous attenuation pattern. Throughout the right medial liver lobe and the left liver lobes, multiple post contrast heterogeneous hyperattenuating zones are visible.

DATE

2-13-23

The pancreas is evenly contoured, the pancreatic parenchyma is homogeneous and presents uniform contrast enhancement.

The position, delineation, wall and content of the gastrointestinal tract are considered within normal limits throughout.

The lumbosacral intervertebral disc is bulging into the vertebral canal, occupying approximately



PATIENT 35% of the cross-sectional area of the vertebral canal at the same level.

Merlin Garnett

COMPUTED TOMOGRAPHIC DIAGNOSIS

SPECIES

Canine

- Hepatic parenchymal nodular lesions
- Suspect left atrial enlargement
- Renal cortical cysts
- Collapsed left principal bronchus
- No evidence of pulmonary metastatic disease

BREED

Kelpie

INTERPRETATION OF THE FINDINGS & FURTHER RECOMMENDATIONS

The hepatic nodular lesions with the strong contrast enhancement pattern in the arterial phase are suggestive for nodular hyperplasia/regeneration nodules. FNA sampling has already performed to screen for neoplastic infiltration.

SEX

MN

The left atrial enlargement is suggestive for volume overload – might be a sequela to general anesthesia with impaired cardiac function or if a cardiac murmur is present mitral valve insufficiency is most common.

AGE

10

INTERPRETED BY

Sebastian Schaub, DVM
Dr. med. vet. DipECVDI

HOSPITAL NAME

Advanced Veterinary
Imaging

REFERRING VET

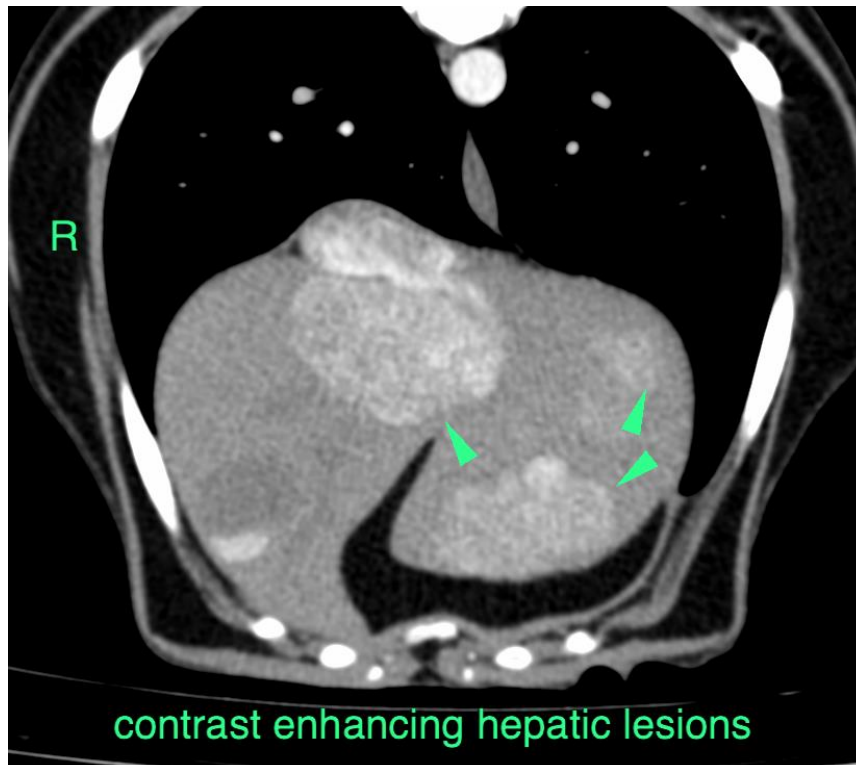
Eamon

INVOICE

56746

DATE

2-13-23





PATIENT

Merlin Garnett

SPECIES

Canine

BREED

Kelpie

SEX

MN

AGE

10

INTERPRETED BY

Sebastian Schaub, DVM
Dr. med. vet. DipECVDI

HOSPITAL NAME

Advanced Veterinary
Imaging

REFERRING VET

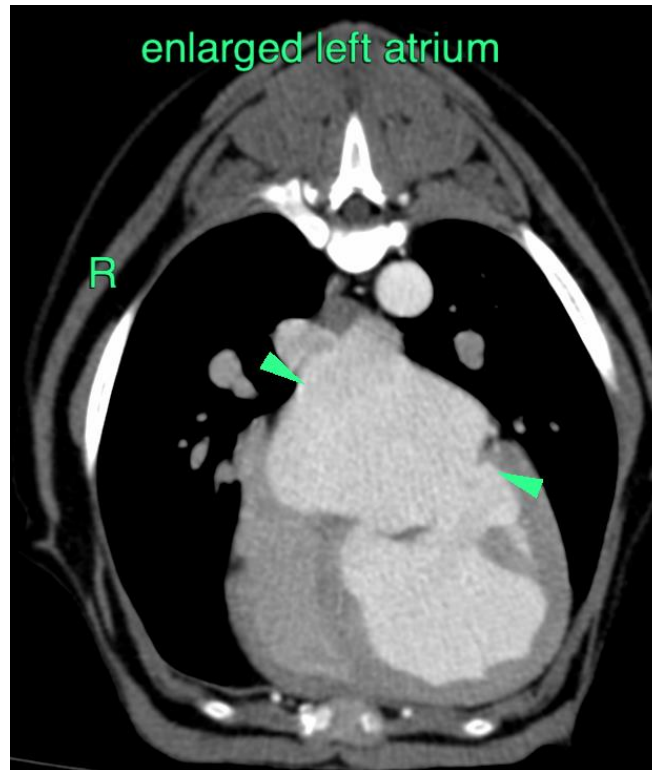Eamon

INVOICE

56746

DATE

2-13-23



The information and recommendations provided are based on the images presented by the referring veterinarian/sonographer. No evaluation can be communicated regarding pathology that was not visible in the image/video clips provided.

Thank you for this referral. If the clinical or image interpretation does not parallel your findings or if I can be of any further assistance please contact me.

Sebastian Schaub, Sebastian Schaub, DVM, Dr. med. vet. DipECVDI
sebast.schaub@gmail.com