



PATIENT

Daisy Mae Geelan

PRESENTING CLINICAL SIGNS

Fluoroscopy study and CT Head/neck and chest performed and submitted 1/24/23-recommended barium swallow study as follow up. Owner reports doing well at home with small, watered down meals being spoon fed at an elevation.

SPECIES

Canine

Abnormal PE/Chem/CBC/UA Results: Studies taken giving barium via syringe, giving canned food mixed with barium, and giving kibble soaked in barium. Patient regurgitated everything after being fed kibble.

BREED

Jack Russell Mix

FLUOROSCOPIC STUDY OF THE NECK AND THORAX

A positive contrast swallowing study is provided for review.

SEX

Female Spayed

The pharyngeal phase of swallowing appears to be normal and the bolus is propelled into the esophagus. No primary nor secondary peristaltic wave is induced by the boluses and the ingested material is pooling in the esophagus – including cervical and thoracic segment.

AGE

1 Year, 10 Months

Level with the cranial thoracic aperture a focal ring shaped narrowing of the contrast stained material in the esophagus is appreciated.

INTERPRETED BY

Sebastian Schaub, DVM
Dr. med. vet. DipECVDI

FLUOROSCOPY DIAGNOSIS & THERAPEUTIC RECOMMENDATIONS

- Ring like narrowing of the esophagus level with the cranial thoracic aperture
- Esophageal dysmotility/megaesophagus
- Aspiration of contrast stained material

INTERPRETATION OF THE FINDINGS & FURTHER RECOMMENDATIONS

The current fluoroscopic study in comparison to the previous CT study presents lack of motility of the esophagus – indicating esophageal dysmotility (common source is esophagitis) or megaesophagus (e.g. neuromuscular disorder). There is a relative stationary ring shaped narrowing of the esophagus level with the cranial thoracic aperture highly suggestive for esophageal stricture. Esophagoscopy can be used for further evaluation and decision making if balloon dilation might be an option.

HOSPITAL NAME

Catskill Veterinary
Services, PLLC

REFERRING VET

Dr. Joseph
D'Abbraccio

INVOICE

56723

DATE

2-13-23



PATIENT

Daisy Mae Geelan

SPECIES

Canine

BREED

Jack Russell Mix

SEX

Female Spayed

AGE

1 Year, 10 Months

INTERPRETED BY

Sebastian Schaub, DVM
Dr. med. vet. DipECVDI

HOSPITAL NAME

Catskill Veterinary
Services, PLLC

REFERRING VET

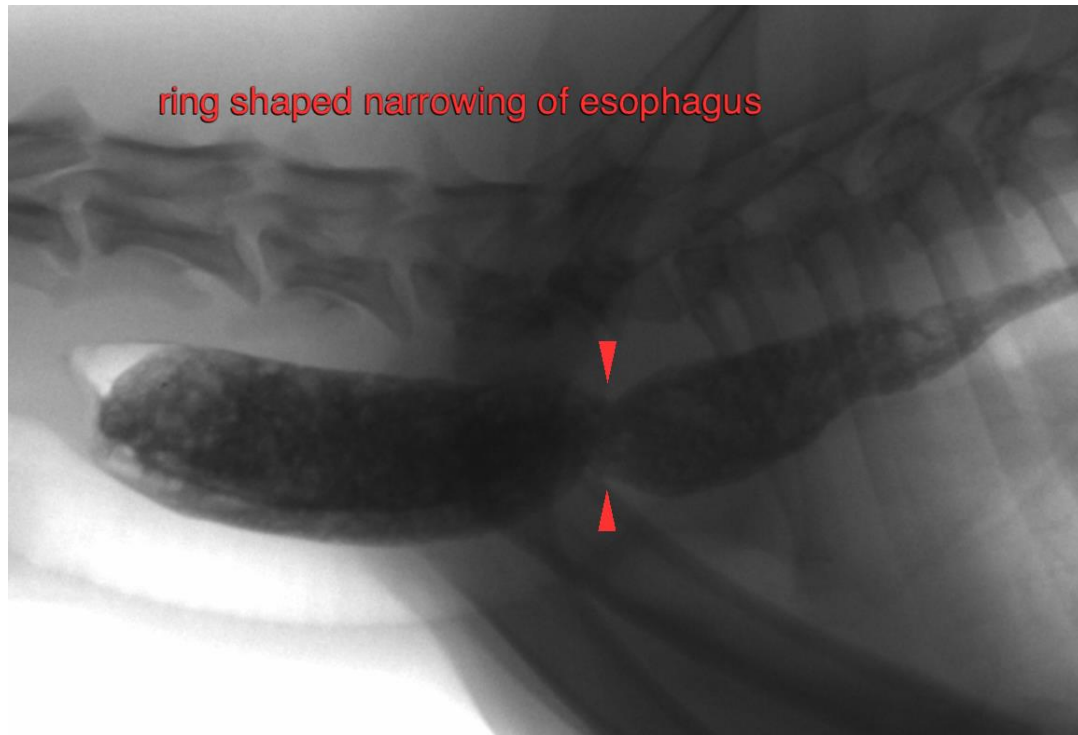
Dr. Joseph
D'Abbraccio

INVOICE

56723

DATE

2-13-23



The information and recommendations provided are based on the images presented by the referring veterinarian/sonographer. No evaluation can be communicated regarding pathology that was not visible in the image/video clips provided.

Thank you for this referral. If the clinical or image interpretation does not parallel your findings or if I can be of any further assistance please contact me.

Sebastian Schaub, Sebastian Schaub, DVM, Dr. med. vet. DipECVDI
sebast.schaub@gmail.com