



PATIENT

Yoda Goedecken

SPECIES

Feline

BREED

Main Coon

SEX

MN

AGE

9Y, 6M

WEIGHT

15.125

INTERPRETED BY

Sebastian Schaub, DVM
Dr. med. vet.
DipECVDI

IMAGING PERFORMED BY

AF

HOSPITAL NAME

Gentle Doctor Animal
Hospital

REFERRING VET

Megan Belfiore

INVOICE

73723

DATE

2-12-26

PRESENTING CLINICAL SIGNS

- Intermittent cough for 2-3 months
- Dry, non-productive
- Did improve with trial of steroid anti-inflammatory, but quickly returned off medications
- Weight stable, no fever, no labwork

RADIOGRAPHIC STUDY OF THE THORAX

Radiographs of the thorax in three imaging planes are provided for review.

RADIOGRAPHIC FINDINGS

The body condition score is 8/9.

The surrounding bony structures are within normal limits.

The extrathoracic soft tissues present homogeneous without abnormalities.

The heart is of normal size and shape; there is no evidence of cardiac chamber or vascular enlargement. The pulmonary vasculature is within normal limits.

The trachea is normal in diameter and presents the anticipated course. The luminal outline of the trachea is smooth.

The bronchial tree presents a generalized mild increased visibility of the walls.

The lung parenchyma presents the expected architecture and opacity; the intrapulmonary vascular branching is seen up to the third order lung vessels.

The diaphragm is well delineated with even surface and the expected mild cranial bulging of the diaphragmatic cupola.

RADIOGRAPHIC DIAGNOSIS

- Equivocal bronchial pattern without air-trapping
- Obesity

INTERPRETATION OF THE FINDINGS & FURTHER RECOMMENDATIONS

The appreciated bronchial pattern can still present normal age related changes of the bronchial tree, the most likely differential is feline bronchial disease – commonly primary allergic.



PATIENT

Yoda Goedecken

SPECIES

Feline

BREED

Main Coon

SEX

MN

AGE

9Y, 6M

WEIGHT

15.125

INTERPRETED BY

Sebastian Schaub, DVM
Dr. med. vet.
DipECVDI

IMAGING PERFORMED BY

AF

HOSPITAL NAME

Gentle Doctor Animal
Hospital

REFERRING VET

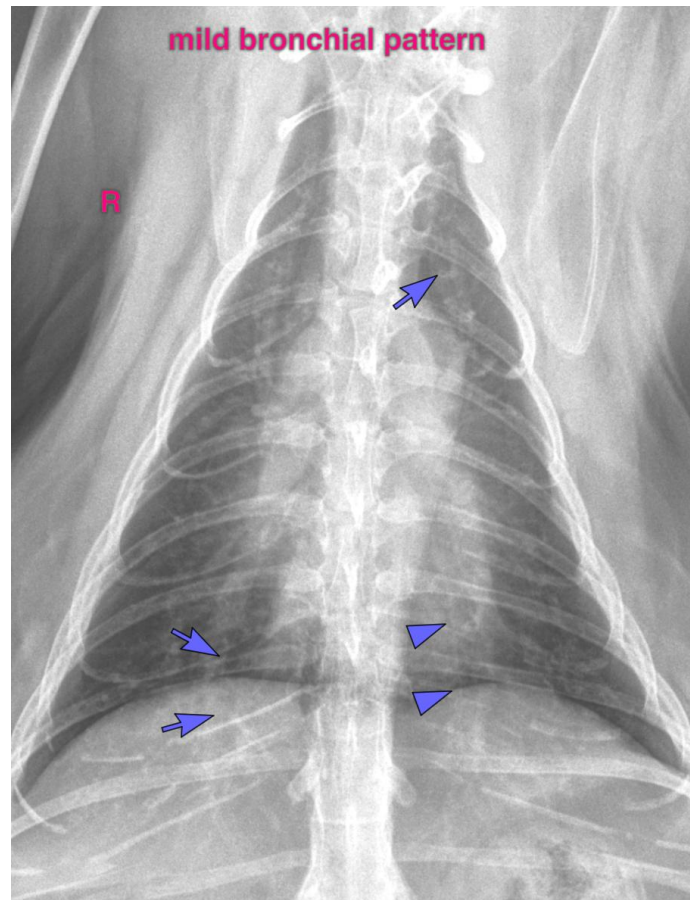
Megan Belfiore

INVOICE

73723

DATE

2-12-26



The information and recommendations provided are based on the images presented by the referring veterinarian/sonographer. No evaluation can be communicated regarding pathology that was not visible in the image/video clips provided.

Thank you for this referral. If the clinical or image interpretation does not parallel your findings or if I can be of any further assistance please contact me.

Sebastian Schaub, Sebastian Schaub, DVM, Dr. med. vet. DipECVDI
info@sonopath.com