



PATIENT

Buddy Hart

SPECIES

Canine

BREED

Shih Tzu

SEX

NM

AGE

15Y

WEIGHT

18.5lbs

INTERPRETED BY

Sebastian Schaub, DVM
Dr. med. vet.
DipECVDI

IMAGING PERFORMED BY

Jen Amidon

HOSPITAL NAME

The Pet Hospital of
Stratford

REFERRING VET

Dr. David

INVOICE

73734

DATE

2-12-26

PRESENTING CLINICAL SIGNS

- Vomit and diarrhea for 3-4 days, lethargic, trembling/shivering.
- Urinating darker urine in smaller, more frequent amounts.
- No change in food/new treats/table scraps
- PE: nsf

Abnormal PE/Chem/CBC/UA Results: bw/ua/cpl pending

RADIOGRAPHIC STUDY OF THE ABDOMEN

Radiographs of the abdomen in three imaging planes are provided for review.

RADIOGRAPHIC FINDINGS

Superimposed on the neuroforamen L3/L4, a thin mineral opaque lamella is appreciated.

No abnormalities of the extraabdominal soft tissues are noted. The abdominal wall is smooth and thin.

The serosal detail is maintained throughout the peritoneal and retroperitoneal space.

The liver is appropriate in position, size and presents uniform opacity.

The splenic head is in the anticipated position and within normal limits for size and opacity. The splenic body and tail are considered normal for position, size, shape and opacity.

Both kidneys are seen and present with normal size, shape, delineation and opacity. A small amount of mineral opaque material is seen in the image plane of the right kidney. The urinary bladder is in its anticipated position. No radiopaque calculi are noted throughout the lower urinary tract. The prostate is prominent and presents faint granular mineralization.

The stomach is in its anticipated position and presents normal content.

The small intestinal loops are of even diameter and non-dilated, a small amount of gas is seen within the small intestinal loops and considered within normal limits.

The colon is seen in the expected position and presents with appropriate content.

RADIOGRAPHIC DIAGNOSIS

- Prominent prostate with possible dystrophic mineralization.
- Mineral opaque material superimposed on neuroforamen L3/L4
- Nephrolithiasis

INTERPRETATION OF THE FINDINGS & FURTHER RECOMMENDATIONS

The prostate is prominent and along with the supposed mineralization the odds for primary neoplastic transformation of the prostate are high – such as adenocarcinoma or transitional cell carcinoma.

Workup can be complemented by a digital rectal examination ± abdominal ultrasound examination. If pathology of the prostate can be confirmed FNA sampling/TruCut biopsy or traumatic catheterization/suction biopsy of the prostatic urethra can be used as advanced diagnostic tools. Testing for BRAF mutation may be considered as well.

The mineral opaque material superimposed on the neuroforamen L3/L4 can present mineralized disc material, lateral spondylosis formation or superimposed dystrophic soft tissue mineralization.



PATIENT

Buddy Hart

SPECIES

Canine

BREED

Shih Tzu

SEX

NM

AGE

15Y

WEIGHT

18.5lbs

INTERPRETED BY

Sebastian Schaub, DVM
Dr. med. vet.
DipECVDI

IMAGING PERFORMED BY

Jen Amidon

HOSPITAL NAME

The Pet Hospital of
Stratford

REFERRING VET

Dr. David

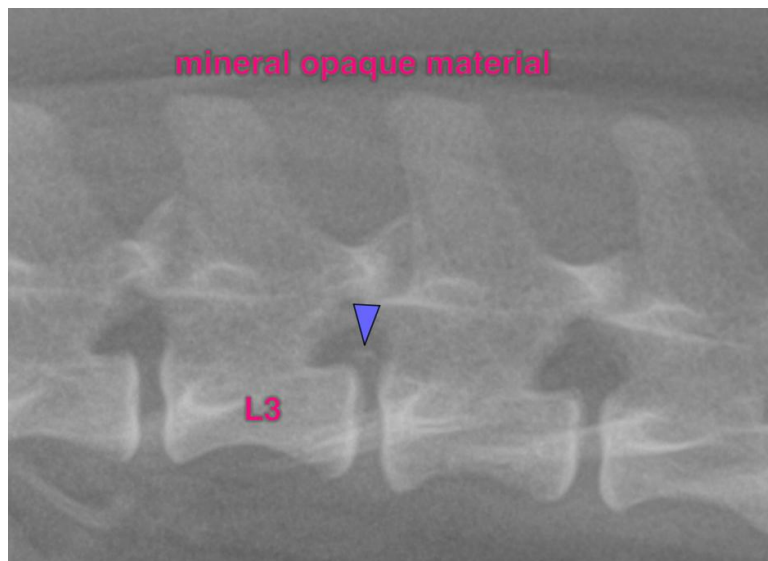
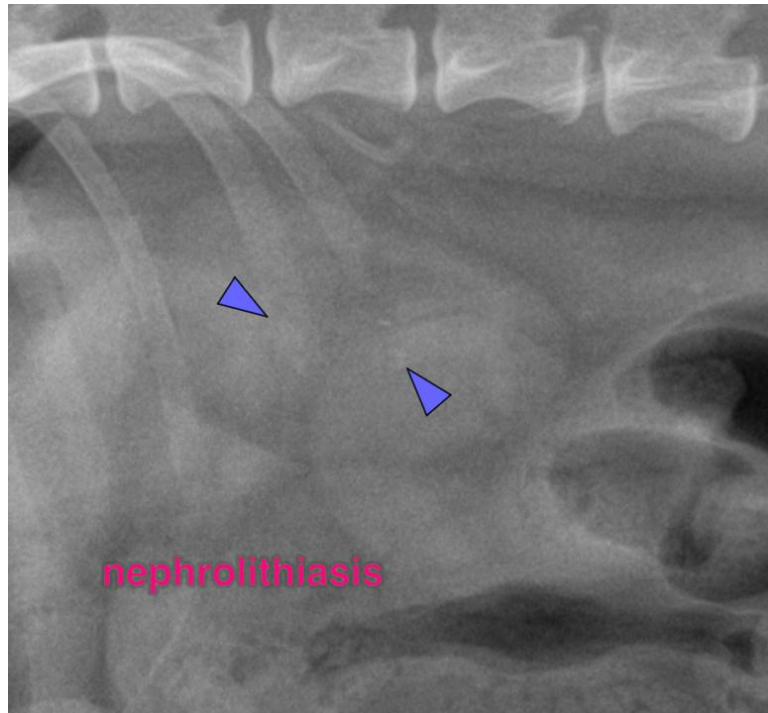
INVOICE

73734

DATE

2-12-26

There is no evidence of radiopaque foreign material, abnormal gas pattern or signs for gastrointestinal mechanical obstruction.





PATIENT

Buddy Hart

SPECIES

Canine

BREED

Shih Tzu

SEX

NM

AGE

15Y

WEIGHT

18.5lbs

INTERPRETED BY

Sebastian Schaub, DVM
Dr. med. vet.
DipECVDI

IMAGING PERFORMED BY

Jen Amidon

HOSPITAL NAME

The Pet Hospital of
Stratford

REFERRING VET

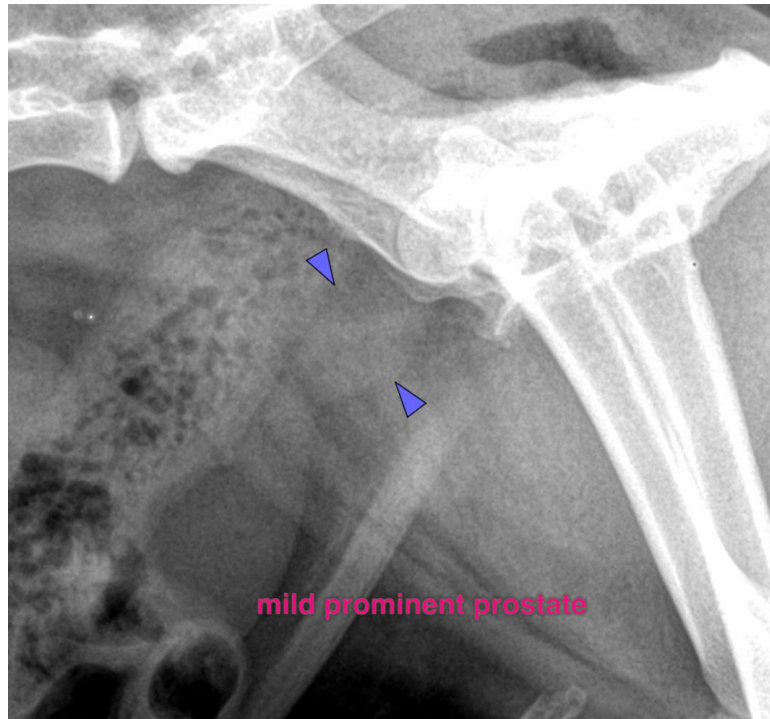
Dr. David

INVOICE

73734

DATE

2-12-26



The information and recommendations provided are based on the images presented by the referring veterinarian/sonographer. No evaluation can be communicated regarding pathology that was not visible in the image/video clips provided.

Thank you for this referral. If the clinical or image interpretation does not parallel your findings or if I can be of any further assistance please contact me.

Sebastian Schaub, Sebastian Schaub, DVM, Dr. med. vet. DipECVDI
info@sonopath.com