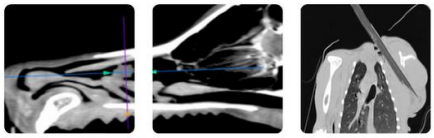

Teleradiology
Educational Teleconsultation Services™

PATIENT
Argus Higgins

SPECIES
Canine

BREED
Lab Mix

SEX
MN

AGE
8

WEIGHT
20

INTERPRETED BY
Sebastian Schaub, DVM
Dr. med. vet.
DipECVDI

IMAGING PERFORMED BY
David

HOSPITAL NAME
Animal Surgical Center - Oceanside

REFERRING VET
Kam

INVOICE
73712

DATE
2-11-26

PRESENTING CLINICAL SIGNS

- intermittent left thoracic limb lameness
- history of right shoulder OCD removal
- left elbow joint thickening

COMPUTED TOMOGRAPHY OF THE SHOULDER AND ELBOW JOINTS

A high resolution post-contrast CT study of the front limbs is provided for review.

COMPUTED TOMOGRAPHIC FINDINGS

The left shoulder joint presents smooth margins of the periarticular bones. The periarticular bones of the right shoulder joint present mild osteophyte new bone formation. The subchondral bone at the caudal aspect of the right humeral head is mildly irregular.

The left axillary lymph node is mildly prominent.

The periarticular bones of the left elbow joint present moderate osteophyte new bone formation. The medial coronoid process of the left elbow joint is irregularly elongated and has a heterogeneous density. In the proximal aspect of the left flexor muscles of the antebrachium, irregular shell like mineralizations is appreciated.

The periarticular bones of the right elbow joint are smooth. The medial coronoid process of the right elbow joint is well-defined and has a homogeneous density. In the right proximal flexor muscles of the antebrachium, shell like mineralization is appreciated.

COMPUTED TOMOGRAPHIC DIAGNOSIS

- Coronoid disease left elbow joint
- Osteoarthrosis left elbow joint
- Mild lymphadenopathy left axillary lymph node
- Flexorenthesopathy with metaplasia elbow joint bilaterally
- History of surgical management OCD right shoulder joint
- Secondary mild osteoarthrosis right shoulder joint

INTERPRETATION OF THE FINDINGS & FURTHER RECOMMENDATIONS

The elbow dysplasia of the left elbow joint with secondary degenerative joint disease is a plausible explanation for the intermittent left front limb lameness. Due to the mild enlargement of the left axillary lymph node a synovial tap may be performed to rule out septic arthritis of the left elbow joint.

SonoPath
FOSTERING THE ART OF VETERINARY MEDICINE™

SonoPath.com info@sonopath.com 1.800.838.4268

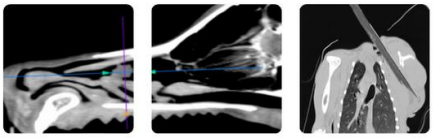

Teleradiology
Educational Teleconsultation Services™

PATIENT

Argus Higgins

SPECIES

Canine

BREED

Lab Mix

SEX

MN

AGE

8

WEIGHT

20

INTERPRETED BY

Sebastian Schaub, DVM
Dr. med. vet.
DipECVDI

IMAGING PERFORMED BY

David

HOSPITAL NAME

Animal Surgical Center - Oceanside

REFERRING VET

Kam

INVOICE

73712

DATE

2-11-26

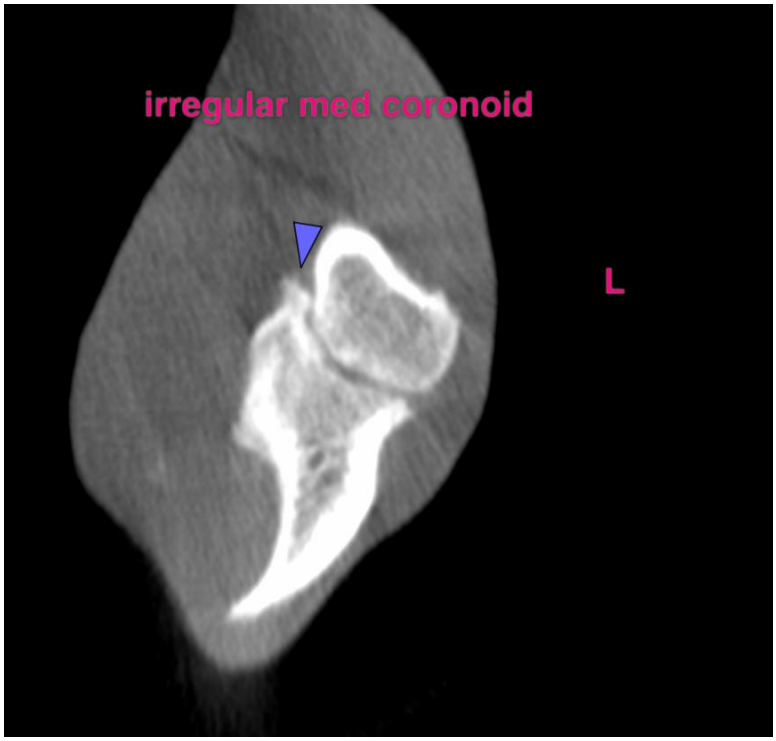

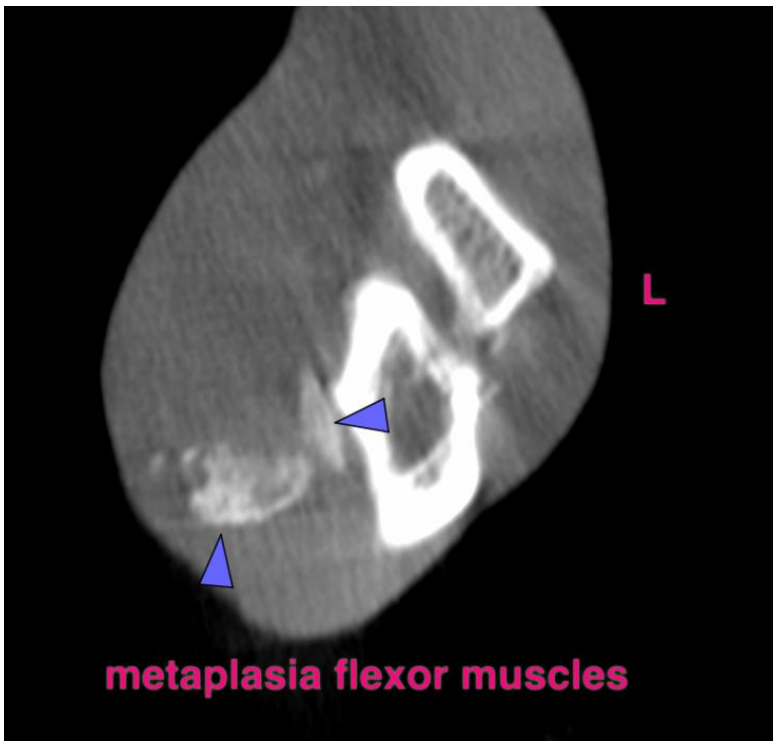

SonoPath
FOSTERING THE ART OF VETERINARY MEDICINE™

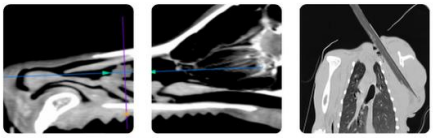

Teleradiology
Educational Teleconsultation Services™

SonoPath.com info@sonopath.com 1.800.838.4268

PATIENT

Argus Higgins

SPECIES

Canine

BREED

Lab Mix

SEX

MN

AGE

8

WEIGHT

20

INTERPRETED BY

Sebastian Schaub, DVM
Dr. med. vet.
DipECVDI

IMAGING PERFORMED BY

David

HOSPITAL NAME

Animal Surgical Center - Oceanside

REFERRING VET

Kam

INVOICE

73712

DATE

2-11-26

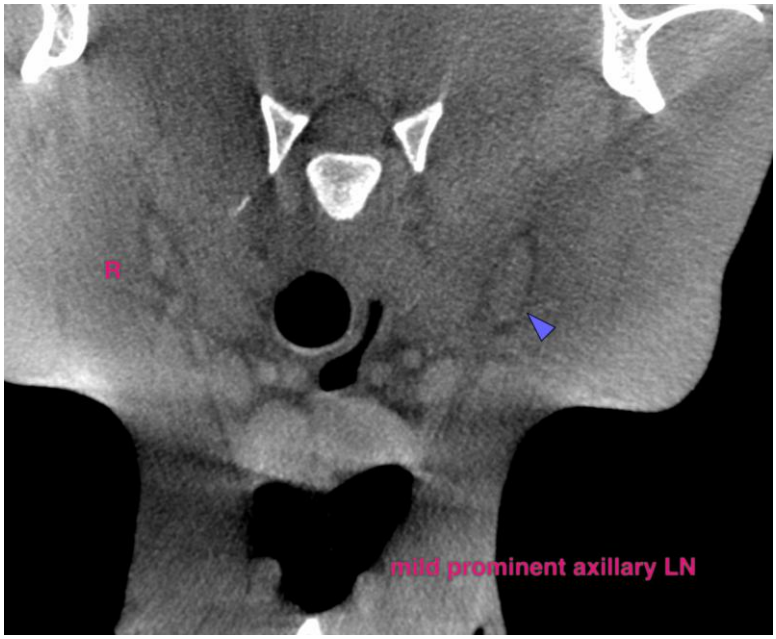

The information and recommendations provided are based on the images presented by the referring veterinarian/sonographer. No evaluation can be communicated regarding pathology that was not visible in the image/video clips provided.

Thank you for this referral. If the clinical or image interpretation does not parallel your findings or if I can be of any further assistance please contact me.

Sebastian Schaub, Sebastian Schaub, DVM, Dr. med. vet. DipECVDI
info@sonopath.com