



**PATIENT**

Bella  
Paraskevopoulos

**SPECIES**

Canine

**BREED**

King Charles Spaniel

**SEX**

Female Spayed

**AGE**

5

**INTERPRETED BY**

Sebastian Schaub, DVM  
Dr. med. vet. DipECVDI

**HOSPITAL NAME**

St. Catherine's Animal  
Hospital

**REFERRING VET**

Dr. Boctor

**INVOICE**

56689

**DATE**

2-11-23

**PRESENTING CLINICAL SIGNS**

tail was run over by 50lbs tricycle.

**RADIOGRAPHIC STUDY OF THE PELVIS**

Radiographs of the pelvis/tail two orthogonal imaging planes.

**RADIOGRAPHIC FINDINGS**

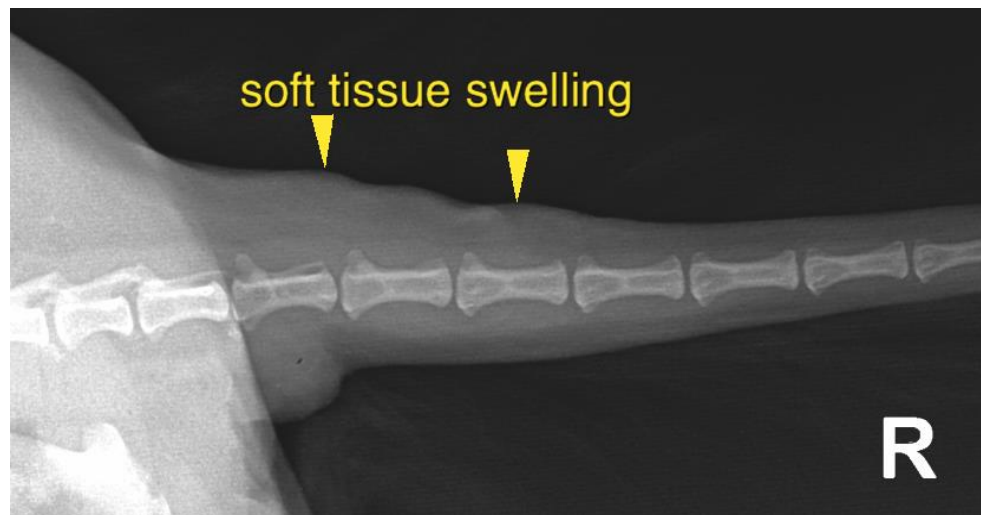
A mild irregular swelling of the subcutaneous tissue dorsal to the cranial third of the tail is appreciated. The osseous structures of the tail present without abnormalities.

**RADIOGRAPHIC DIAGNOSIS**

- Soft tissue swelling cranial segment of the tail
- No evidence of fracture or luxation

**INTERPRETATION OF THE FINDINGS & FURTHER RECOMMENDATIONS**

The soft tissue swelling can be a sequela to the trauma with subcutaneous hematoma/edematous swelling. No additional clinically relevant abnormalities are appreciated.





**PATIENT**

Bella  
Paraskevopoulos

The information and recommendations provided are based on the images presented by the referring veterinarian/sonographer. No evaluation can be communicated regarding pathology that was not visible in the image/video clips provided.

Thank you for this referral. If the clinical or image interpretation does not parallel your findings or if I can be of any further assistance please contact me.

**SPECIES**

Canine

**Sebastian Schaub**, Sebastian Schaub, DVM, Dr. med. vet. DipECVDI  
sebast.schaub@gmail.com

**BREED**

King Charles Spaniel

**SEX**

Female Spayed

**AGE**

5

**INTERPRETED BY**

Sebastian Schaub, DVM  
Dr. med. vet. DipECVDI

**HOSPITAL NAME**

St. Catherine's Animal  
Hospital

**REFERRING VET**

Dr. Boctor

**INVOICE**

56689

**DATE**

2-11-23