



**PATIENT PRESENTING CLINICAL SIGNS**

**Salem Pawar** History: sudden onset of weakness, especially in the forelimbs On Phenobarbital for seizures, well controlled.

**SPECIES** Abnormal PE/Chem/CBC/UA Results: Muscle atrophy appreciated in the front limbs no ataxia no cranial nerve deficits No proprioceptive deficits, no neck or back pain

Canine

**RADIOGRAPHIC STUDY OF THE NECK AND FRONT LIMBS**

**BREED** Radiographs of the neck and front limbs are provided for review.

**Husky X RADIOGRAPHIC FINDINGS**

**SEX** Generalized moderate spondylosis formation is present along the cervical spine. The intervertebral disc space C6/C7 is narrowed.

**Spayed Female** The osseous structures of both front limbs are within normal limits and the shoulder and elbow joints present smooth osseous margins.

**AGE** At the lateral aspect of the right antebrachium a small cutaneous swelling is visible, approximately level with the mid diaphysis of the radius/ulna.  
13 Years

**RADIOGRAPHIC DIAGNOSIS**

**INTERPRETED BY**

- Discopathy C6/C7
- Spondylosis deformans cervical spine
- Normal front limbs but focal cutaneous swelling lateral aspect right antebrachium, rule out small cutaneous mass

Sebastian Schaub,  
DVM Dr. med. vet.  
DipECVDI

**HOSPITAL NAME**

**INTERPRETATION OF THE FINDINGS & FURTHER RECOMMENDATIONS**

**Balmy Beach PH** The discopathy C6/C7 might be associated with compressive myelopathy as cause for the described clinical signs. Based on the development of clinical signs and results of the neurological examination, cross-sectional imaging might be used to rule in/out compressive myelopathy

**REFERRING VET**

Dr. Singh

**INVOICE**

13909

**DATE**

2/11/22



**PATIENT**

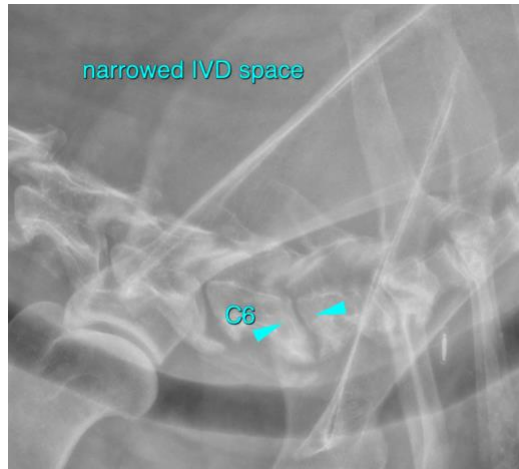
Salem Pawar

**SPECIES**

Canine

**BREED**

Husky X



**SEX**

Spayed Female

**The information and recommendations provided are based on the images presented by the referring veterinarian/sonographer. No evaluation can be communicated regarding pathology that was not visible in the image/video clips provided.**

**AGE**

13 Years

Thank you for this referral. If the clinical or image interpretation does not parallel your findings or if I can be of any further assistance please contact me.

**Sebastian Schaub**, Sebastian Schaub, DVM, Dr. med. vet. DipECVDI  
sebast.schaub@gmail.com

**INTERPRETED BY**

Sebastian Schaub,  
DVM Dr. med. vet.  
DipECVDI

**HOSPITAL NAME**

Balmy Beach PH

**REFERRING VET**

Dr. Singh

**INVOICE**

13909

**DATE**

2/11/22