



PATIENT PRESENTING CLINICAL SIGNS

Ranger Hardgrove History: Acute onset limping on LH leg
Abnormal PE/Chem/CBC/UA Results:

SPECIES RADIOGRAPHIC STUDY OF THE LEFT STIFLE JOINT

Canine Radiographs of the left stifle joint in two orthogonal imaging planes are provided for review.

RADIOGRAPHIC FINDINGS

BREED

Poodle Mix

Moderate widening of the apophysis of the left tibial tuberosity and the cranial aspect of the proximal epiphysis of the left tibia is visible. In the craniocaudal projection there is a possible perpendicular fissure line running through the mid aspect of the left tibial plateau. At the caudal aspect of the proximal tibial metaphysis, a small isolated osseous fragment is visible.

SEX

Male

RADIOGRAPHIC DIAGNOSIS

- Acute traumatic closed, left proximal tibial apo- and epiphysiolysis (Salter-Harris Type II or IV fracture)

AGE

5 Months

INTERPRETATION OF THE FINDINGS & FURTHER RECOMMENDATIONS

The findings are consistent with traumatic fracture of the growth plates of the left tibial tuberosity and the tibial plateau. There is some uncertainty if there is a fissure line running through the left tibial plateau – follow up radiographs can be used for re-evaluation. Surgical stabilization is the therapy of choice and options should be discussed with orthopedic surgeon.

INTERPRETED BY

Sebastian Schaub,
DVM Dr. med. vet.
DipECVDI

HOSPITAL NAME

Rockaway AH

REFERRING VET

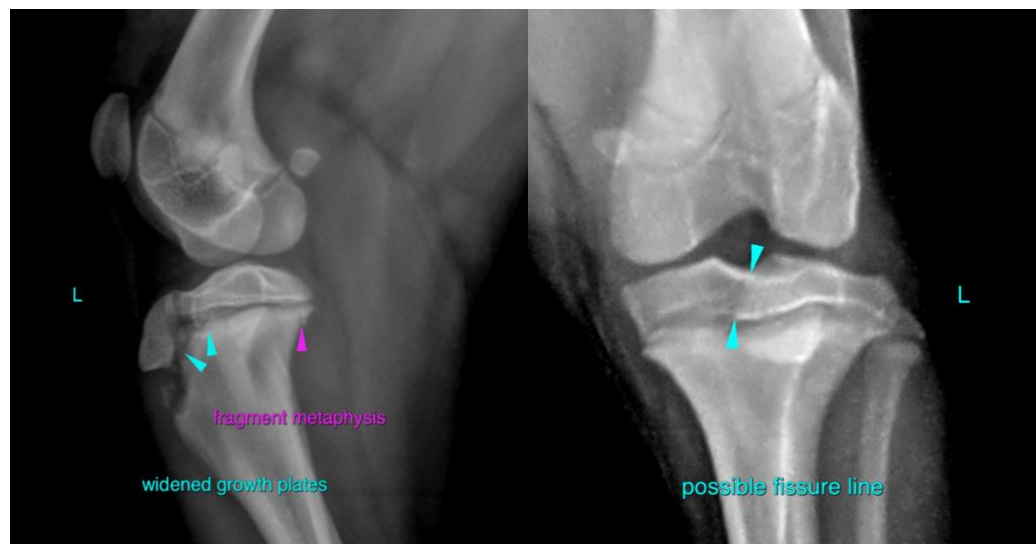
Dr. Kahn

INVOICE

13911

DATE

2/11/22





PATIENT

Ranger Hardgrove

The information and recommendations provided are based on the images presented by the referring veterinarian/sonographer. No evaluation can be communicated regarding pathology that was not visible in the image/video clips provided.

SPECIES

Canine

Thank you for this referral. If the clinical or image interpretation does not parallel your findings or if I can be of any further assistance please contact me.

Sebastian Schaub, Sebastian Schaub, DVM, Dr. med. vet. DipECVDI
sebast.schaub@gmail.com

BREED

Poodle Mix

SEX

Male

AGE

5 Months

INTERPRETED BY

Sebastian Schaub,
DVM Dr. med. vet.
DipECVDI

HOSPITAL NAME

Rockaway AH

REFERRING VET

Dr. Kahn

INVOICE

13911

DATE

2/11/22