



**PATIENT PRESENTING CLINICAL SIGNS**

Princessa Cepero History: Nasal congestion, swelling between eyes, suspect nasal mass.  
Abnormal PE/Chem/CBC/UA Results: Mild epistaxis noted post CT

**SPECIES COMPUTED TOMOGRAPHIC STUDY OF THE SKULL**

Canine A high resolution pre- and post-contrast CT study of the skull is for review.

**COMPUTED TOMOGRAPHIC FINDINGS**

**BREED**

Min Pinscher The tooth elements 101, 102, 105-107, 201-203, 205-207, 302, 303, 402, 403, 406, 408 and 411 are absent.

**SEX**

Spayed Female The left nasal cavity is occupied by a soft tissue attenuating and heterogeneous moderate contrast enhancing mass. Advanced destruction of the left nasal conchal & turbinate structures is visible. The nasal septum is deviated to the right by the mass effect. There is aggressive osteolysis of the left nasal, palatine & maxillary bone and the nasal mass is bulging into the subcutaneous tissue at the dorsal aspect of the nose and submucosa of the hard palate. The cribriform plate is intact.

**AGE**

11 Years 8 Months Both temporomandibular joints present congruent joint spaces with even subchondral bone surfaces and are considered within normal limits.

Both tympanic bullae are aerated, the mucosal lining is not seen, the bony wall is smooth and thin. The external ear canals are within normal limits.

**INTERPRETED BY**

Sebastian Schaub, DVM Dr. med. vet. DipECVDI The brain presents no deviation from normal anatomy and symmetry. The brain parenchyma is homogeneous and within normal limits for attenuation and distribution of contrast enhancement. The ventricular system is non-dilated and symmetric.

**HOSPITAL NAME**

The mandibular lymph nodes are prominent.

**REFERRING VET**

**COMPUTED TOMOGRAPHIC DIAGNOSIS**

- Left sided biologically aggressive nasal soft tissue neoplasia
- Secondary polyostotic aggressive osteolytic lesions of the osseous structures of the nose
- Lymphadenopathy mandibular lymph nodes
- Multiple absent teeth, see above

**INTERPRETATION OF THE FINDINGS & FURTHER RECOMMENDATIONS**

**INVOICE**

13910 Potentials for the nasal neoplasm include adenocarcinoma, lymphosarcoma, squamous cell carcinoma, transitional cell sarcoma, other. FNA sampling of the tissue protruding into the subcutaneous tissue can be performed as minimally invasive advanced diagnostic test. Rhinoscopy including biopsy is feasible as well. Based on biopsy results, the chances of radiation therapy might be discussed with oncologist; the Adam tumor stage is T3.

**DATE**

2/11/22



**PATIENT**

Princessa Cepero

Recommend complementing full tumor staging by FNA sampling of the regional lymph nodes and 3-view thoracic radiographs.

**SPECIES**

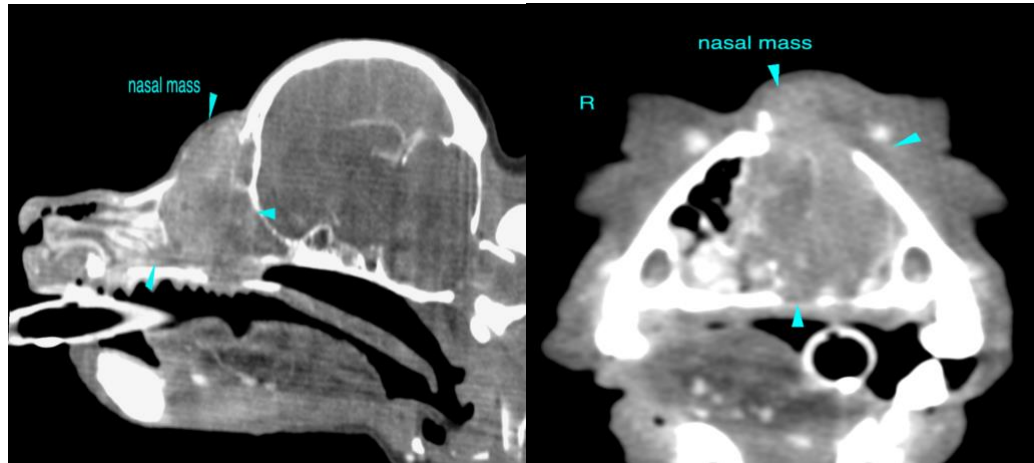
Canine

**BREED**

Min Pinscher

**SEX**

Spayed Female



**AGE**

11 Years 8 Months

The information and recommendations provided are based on the images presented by the referring veterinarian/sonographer. No evaluation can be communicated regarding pathology that was not visible in the image/video clips provided.

**INTERPRETED BY**

Sebastian Schaub,  
DVM Dr. med. vet.  
DipECVDI

Thank you for this referral. If the clinical or image interpretation does not parallel your findings or if I can be of any further assistance please contact me.

**Sebastian Schaub**, Sebastian Schaub, DVM, Dr. med. vet. DipECVDI  
sebast.schaub@gmail.com

**HOSPITAL NAME**

Mobile Pet Imaging

**REFERRING VET**

Dr. Meaux

**INVOICE**

13910

**DATE**

2/11/22