SonoPath Teleradiology

EDUCATIONAL TELECONSULTATION SERVICES™

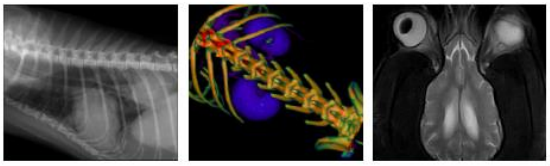

SonoPath.com
1-800-838-4268 info@sonopath.com

PATIENT

Itheral Koll

SPECIES

Feline

BREED

DSH

SEX

Neutered Male

AGE

9 Years

INTERPRETED BY

Sebastian Schaub, DVM Dr. med. vet. DipECVDI

HOSPITAL NAME

New Bridge VP

REFERRING VET

Dr. Abina Glennon

INVOICE

13908

DATE

2/11/22

PRESENTING CLINICAL SIGNS

History: "Wet cough" and wheezing...
Abnormal PE/Chem/CBC/UA Results: Pending

RADIOGRAPHIC STUDY OF THE THORAX

A lateral projection of the thorax is provided for review.

RADIOGRAPHIC FINDINGS

The surrounding bony structures are within normal limits.

The extrathoracic soft tissues present homogeneous without abnormalities.

The heart is of normal size and shape, there is no evidence of cardiac chamber or vascular enlargement. The pulmonary vasculature is within normal limits.

The trachea is normal in diameter and presents the anticipated course. The luminal outline of the trachea is smooth.

Generalized moderate peribronchial cuffing is seen.

The lung parenchyma presents the expected architecture and opacity; the intrapulmonary vascular branching is seen up to the third order lung vessels.

The diaphragm is well delineated with even surface and the expected mild cranial bulging of the diaphragmatic cupola.

RADIOGRAPHIC DIAGNOSIS

- Moderate bronchial lung pattern without evidence of air-trapping

INTERPRETATION OF THE FINDINGS & FURTHER RECOMMENDATIONS

The findings are compatible with bronchitis and both inflammatory non-infectious causes (e.g., feline bronchial disease) or infectious causes – viral, bacterial, parasitic, protozoal – are considerations. I would consider the odds for infectious cause higher and starting empirical therapy including antimicrobial drugs appears beneficial.
There are no signs for cardiomegaly.

SonoPath Teleradiology

EDUCATIONAL TELECONSULTATION SERVICES™

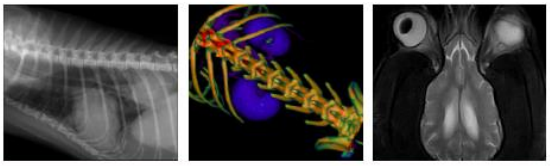

SonoPath.com
1-800-838-4268 info@sonopath.com

PATIENT

Itheral Koll

SPECIES

Feline

BREED

DSH

SEX

Neutered Male

AGE

9 Years

INTERPRETED BY

Sebastian Schaub, DVM Dr. med. vet. DipECVDI

HOSPITAL NAME

New Bridge VP

REFERRING VET

Dr. Abina Glennon

INVOICE

13908

DATE

2/11/22

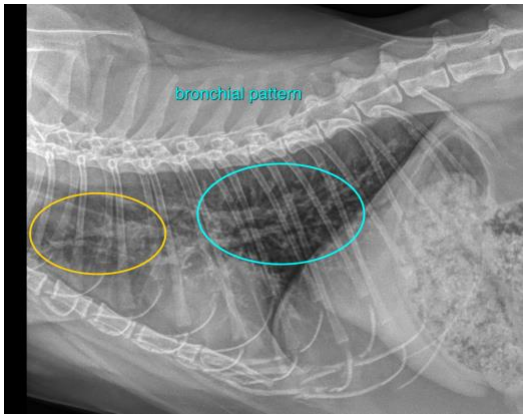

The information and recommendations provided are based on the images presented by the referring veterinarian/sonographer. No evaluation can be communicated regarding pathology that was not visible in the image/video clips provided.

Thank you for this referral. If the clinical or image interpretation does not parallel your findings or if I can be of any further assistance please contact me.

Sebastian Schaub, Sebastian Schaub, DVM, Dr. med. vet. DipECVDI
sebast.schaub@gmail.com