



**PATIENT PRESENTING CLINICAL SIGNS**

Cash Carter History: Animal came to us from Animal Control with a history of seizures. BAR in between seizures. Abnormal PE/Chem/CBC/UA Results: Bloodwork is unremarkable. 4dx negative

**SPECIES COMPUTED TOMOGRAPHIC STUDY OF THE SKULL**

Canine A high-resolution post-contrast CT study of the neurocranium is provided for review.

**COMPUTED TOMOGRAPHIC FINDINGS**

**BREED**

Heeler Mix Both temporomandibular joints present congruent joint spaces with even subchondral bone surfaces and are considered within normal limits.

**SEX**

Both tympanic bullae are aerated, the mucosal lining is not seen, the bony wall is smooth and thin. The external ear canals are within normal limits.

**Male**

The brain presents no deviation from normal anatomy and symmetry. The brain parenchyma is homogeneous and within normal limits for attenuation and distribution of contrast enhancement. The ventricular system is non-dilated and symmetric.

**AGE**

2 Years The submandibular and medial retropharyngeal lymph nodes are small and elongated with a normal short-to-long-axis-ratio is < 0.5, the attenuation and contrast enhancement pattern are uniform.

**INTERPRETED BY**

Sebastian Schaub,  
DVM Dr. med. vet.  
DipECVDI

**COMPUTED TOMOGRAPHIC DIAGNOSIS**

- Structural normal brain

**HOSPITAL NAME**

Petroglyph AH

**INTERPRETATION OF THE FINDINGS & FURTHER RECOMMENDATIONS**

In the present study of the brain there is no evidence of macromorphological disease, which supports the presumptive diagnosis of idiopathic epilepsy.

**REFERRING VET**

Dr. Alice Ku

If not yet done so the workup should be complemented by examination of CSF and complete bloodwork to screen for brain disease that is not necessarily associated with structural changes of the brain parenchyma and rule out hepatoencephalopathy and other systemic illness. In case of the strong clinical suspicion of structural intraparenchymal changes an MRI may be considered.

**INVOICE**

13890

**DATE**

2/11/22



**PATIENT**

Cash Carter

**SPECIES**

Canine

**BREED**

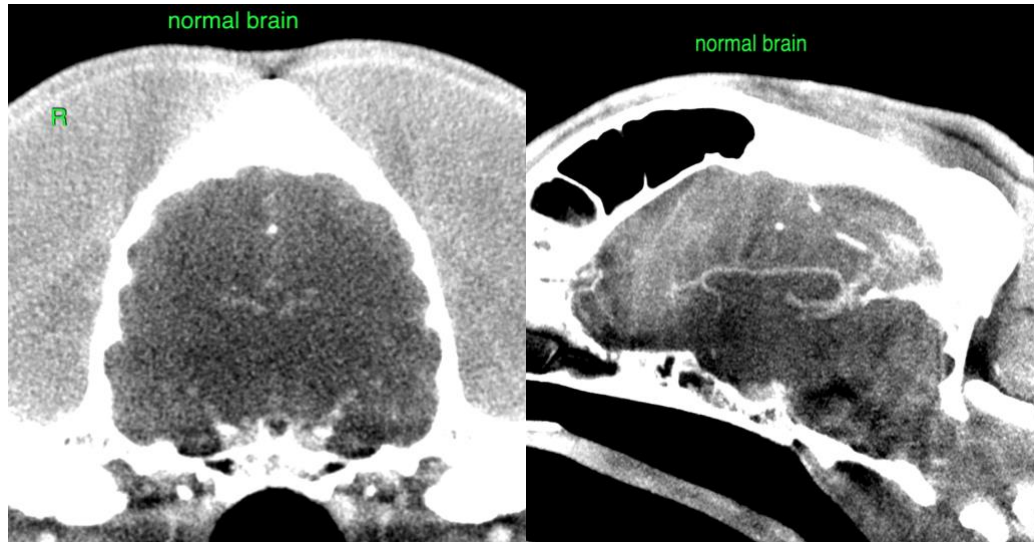
Heeler Mix

**SEX**

Male

**AGE**

2 Years



**The information and recommendations provided are based on the images presented by the referring veterinarian/sonographer. No evaluation can be communicated regarding pathology that was not visible in the image/video clips provided.**

Thank you for this referral. If the clinical or image interpretation does not parallel your findings or if I can be of any further assistance please contact me.

**INTERPRETED BY**

Sebastian Schaub,  
DVM Dr. med. vet.  
DipECVDI

**Sebastian Schaub**, Sebastian Schaub, DVM, Dr. med. vet. DipECVDI  
sebast.schaub@gmail.com

**HOSPITAL NAME**

Petroglyph AH

**REFERRING VET**

Dr. Alice Ku

**INVOICE**

13890

**DATE**

2/11/22