



PATIENT PRESENTING CLINICAL SIGNS

Abbie Rose Greenwell History: History: O SAID P NUDGE HER WAY INTO THE POOL (LOVES TO SWIM), 2 WEEKS AGO BEGAN LIMPING, P SEEMS TO LIMP ON ONE OF THE HIND LEGS, UNSURE WHICH LEG, O IS GIVING P GALLIPRANT 60MG 1 TAB SID (CAN WE INCREASE DOSE?) AND GOING ON SHORTER WALKS

SPECIES

Canine Abnormal PE/Chem/CBC/UA Results: Physical Examination Key -- (N= Normal, A= Abnormal)
 Hydration: N Mentation: N EENT: N Oral Cavity: N Lymph Nodes: N Skin: N CV/Respiratory: N
 Abd/GI: N Uro/Perineum: N Musculoskeletal: Weightbearing mild left rear lameness. When sits puts left rear out to side. Medial buttress both stifles, positive drawer left stifle, subtle crepitus left stifle.

BREED

Neurological: N

English Springer Spaniel

RADIOGRAPHIC STUDY OF THE STIFLE JOINTS

Radiographs of the stifle joints in two orthogonal imaging planes are provided for review.

SEX

RADIOGRAPHIC FINDINGS

Spayed Female

The volume of the soft tissue shadow of the left thigh musculature is moderately decreased.

AGE

The periarticular bones of the left stifle joint present moderate osteophyte new bone formation and a moderate intracapsular soft tissue swelling of the left stifle joint is appreciated.

10 Years 5 Months

The right stifle joint has smooth osseous margins, a mild intracapsular swelling of the right stifle joint is appreciated.

INTERPRETED BY

RADIOGRAPHIC DIAGNOSIS

Sebastian Schaub,
 DVM Dr. med. vet.
 DipECVDI

- Moderate degenerative osteoarthritis left stifle joint
- Moderate articular swelling left stifle joint
- Disuse atrophy left thigh musculature
- Mild articular swelling right stifle joint

HOSPITAL NAME

DPC Veterinary Hospital

INTERPRETATION OF THE FINDINGS & FURTHER RECOMMENDATIONS

REFERRING VET

The radiographic study is consistent with chronic degenerative osteoarthritis with concomitant joint effusion of the left stifle joint. The most-likely underlying cause is (partial) rupture of the cranial cruciate ligament with or without meniscal disease.

Dr. Feldt

A positive drawer sign or tibial compression test under general anesthesia can be used to confirm the diagnosis.

INVOICE

21060

The mild articular swelling of the right stifle joint might indicate early stage of degenerative joint disease/pathology of the cranial cruciate ligament.

DATE

2/10/23



PATIENT

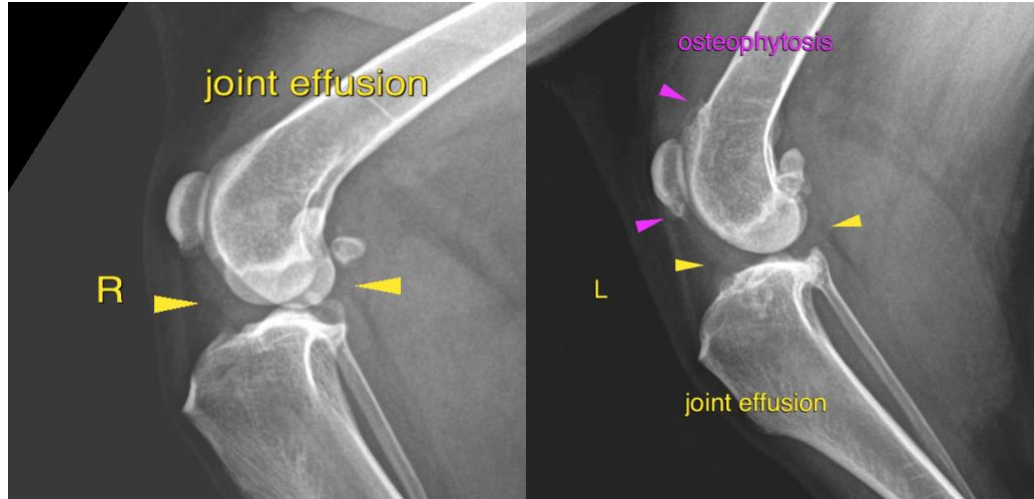
Abbie Rose Greenwell

SPECIES

Canine

BREED

English Springer
Spaniel



SEX

Spayed Female

The information and recommendations provided are based on the images presented by the referring veterinarian/sonographer. No evaluation can be communicated regarding pathology that was not visible in the image/video clips provided.

AGE

10 Years 5 Months

Thank you for this referral. If the clinical or image interpretation does not parallel your findings or if I can be of any further assistance please contact me.

Sebastian Schaub, Sebastian Schaub, DVM, Dr. med. vet. DipECVDI
sebast.schaub@gmail.com

INTERPRETED BY

Sebastian Schaub,
DVM Dr. med. vet.
DipECVDI

HOSPITAL NAME

DPC Veterinary
Hospital

REFERRING VET

Dr. Feldt

INVOICE

21060

DATE

2/10/23