



PATIENT

Blue Gonzalez

PRESENTING CLINICAL SIGNS

P is here for annual check up getting old, legs are stiff, walks slower, maybe an adequan shot today? P also drinks water too fast and will spit up water with some bile but doesn't happen often e/d/u/d ok no c/s/v/d activity slowing down masses over body don't bother him o gives dental sticks but it doesn't seem to help in 2020 he had a FB that had to be removed at ER eats crave GF adult high protein food dry and wet food eukanuba and pedigree sometimes people food
 Abnormal PE/Chem/CBC/UA Results: Low WBCs, Chol 447, ALB 4.5, ALP 194

SPECIES

Canine

RADIOGRAPHIC STUDY OF THE PELVIS AND STIFLE JOINTS

BREED

Pitbull Mix

An overview study including the pelvis & stifle joints in two imaging planes is provided for review. No side markers are present.

RADIOGRAPHIC FINDINGS

SEX

MN

The vertebral endplates of the lumbosacral junction present moderate osteophyte new bone formation.

AGE

12

The osseous and surrounding soft tissue structures of the pelvis are within normal limits. The coxofemoral joints present congruent joint spaces. The right femoral head presents mild osteophyte new bone formation.

INTERPRETED BY

Sebastian Schaub, DVM
 Dr. med. vet. DipECVDI

Both stifle joints present smooth osseous margins without evidence of intracapsular soft tissue swelling. A soft tissue opaque nodule is seen – suspect caudal to the distal femoral diaphysis (unknown side) – the soft tissue nodule is not appreciated in the craniocaudal projection.

RADIOGRAPHIC DIAGNOSIS

HOSPITAL NAME

Animal Paradise
 Hospital

- Degenerative osseous changes lumbosacral junction
- Mild degenerative osteoarthritis right coxofemoral joint, suspect due to 'wear-and-tear'
- Normal stifle joints
- Possible soft tissue nodule thigh of one hind limb

INTERPRETATION OF THE FINDINGS & FURTHER RECOMMENDATIONS

REFERRING VET

Dr. Mostafa Elshafie

The degenerative changes of the lumbosacral junction might be associated with degenerative lumbosacral stenosis, explaining the clinical signs in the hind limbs.

Check the thorax for mass in the right caudal lung lobe.

INVOICE

50009

DATE

2-1-22



PATIENT

Blue Gonzalez

SPECIES

Canine

BREED

Pitbull Mix

SEX

MN

AGE

12

INTERPRETED BY

Sebastian Schaub, DVM
Dr. med. vet. DipECVDI

HOSPITAL NAME

Animal Paradise
Hospital

REFERRING VET

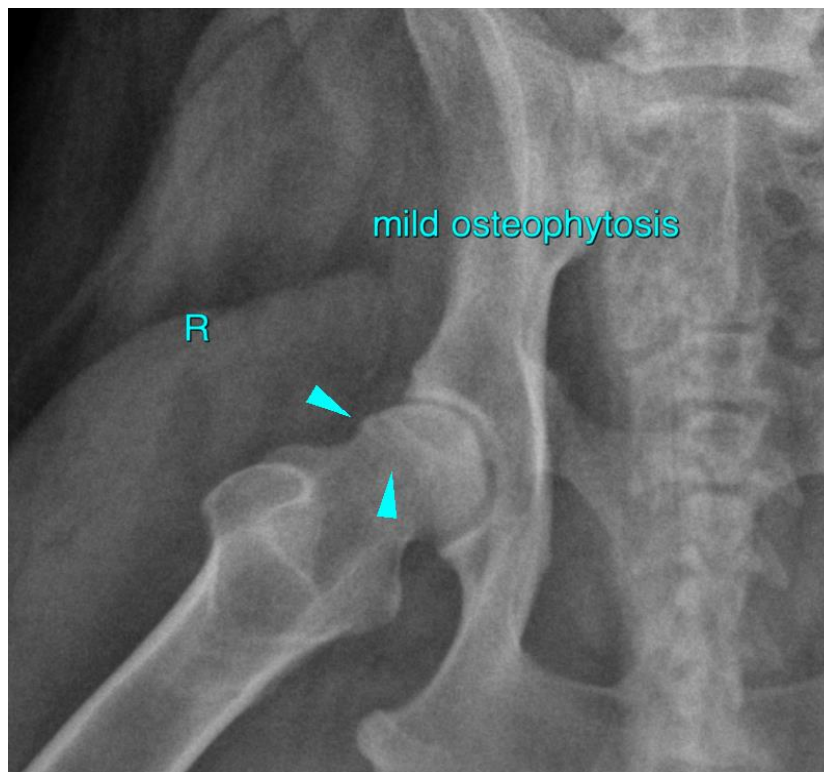
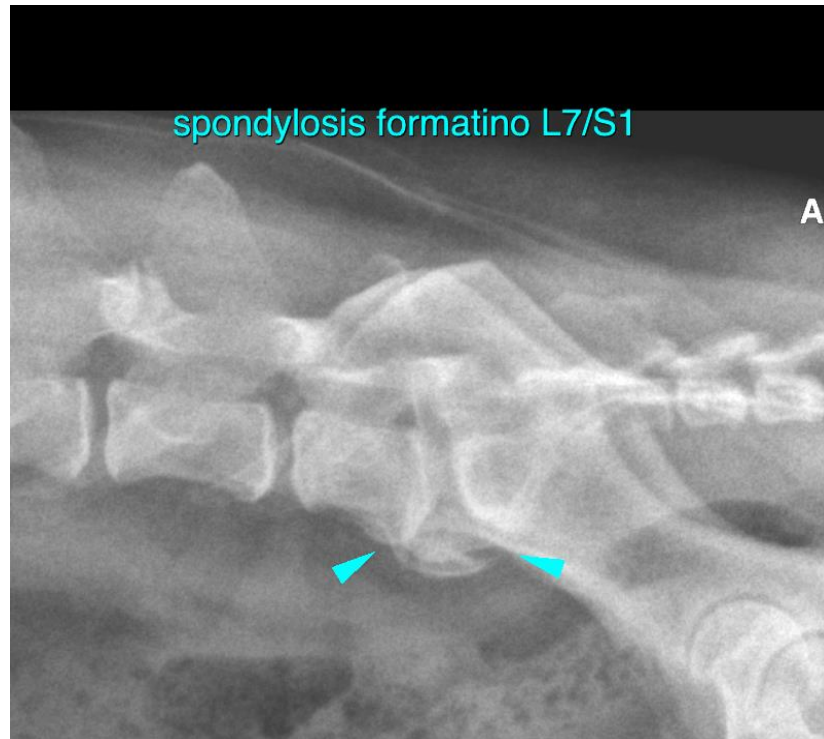
Dr. Mostafa Elshafie

INVOICE

50009

DATE

2-1-22





PATIENT

Blue Gonzalez

SPECIES

Canine

BREED

Pitbull Mix

SEX

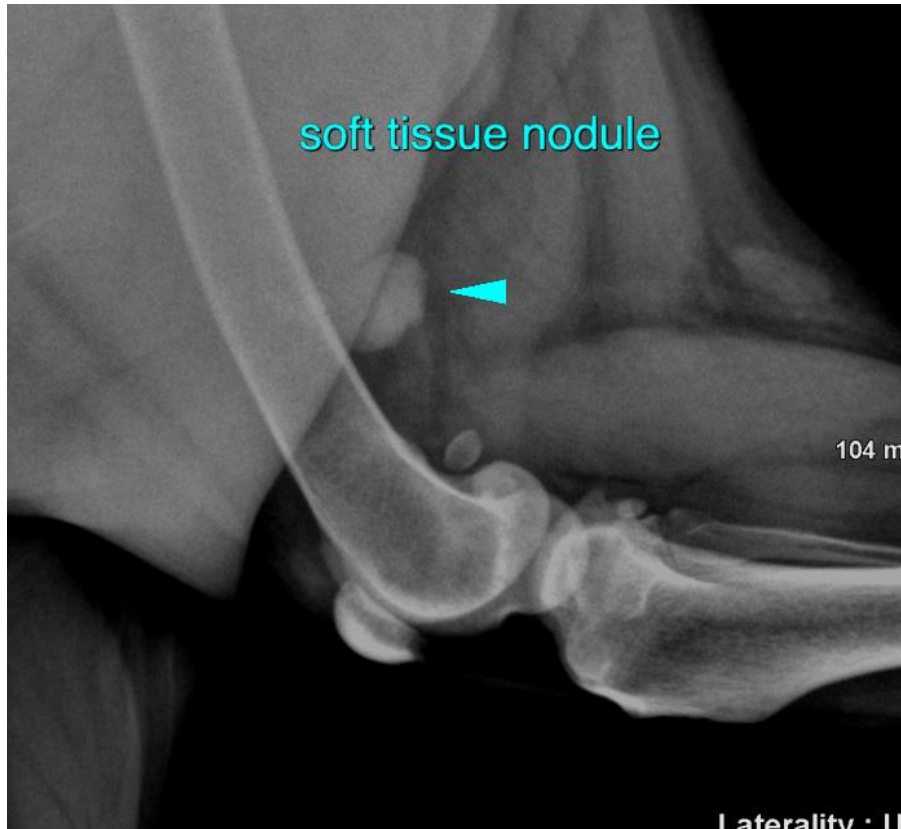
MN

AGE

12

INTERPRETED BY

Sebastian Schaub, DVM
Dr. med. vet. DipECVDI



HOSPITAL NAME

Animal Paradise
Hospital

REFERRING VET

Dr. Mostafa Elshafie

INVOICE

50009

DATE

2-1-22

The information and recommendations provided are based on the images presented by the referring veterinarian/sonographer. No evaluation can be communicated regarding pathology that was not visible in the image/video clips provided.

Thank you for this referral. If the clinical or image interpretation does not parallel your findings or if I can be of any further assistance please contact me.

Sebastian Schaub, Sebastian Schaub, DVM, Dr. med. vet. DipECVDI
sebast.schaub@gmail.com