


PATIENT PRESENTING CLINICAL SIGNS

Eva Hemmer Cranial mediastinal mass.

COMPUTED TOMOGRAPHIC STUDY OF THE THORAX
SPECIES

A high resolution pre- and post-contrast CT study of the thorax is provided for review.

Canine

COMPUTED TOMOGRAPHIC FINDINGS
BREED

Multifocal moderate spondylosis formation is seen along the mid thoracic spine. Both shoulder joints present moderate osteophyte new bone formation. C7 presents abnormally elongated transverse processes.

Rottweiler

SEX

A mild amount of gravity dependent, non-contrast enhancing soft tissue material is visible in the dorsal aspect of the pleural cavity bilaterally and thin pleural fissure lines are appreciated.

Spayed Female

AGE

In the cranioventral mediastinum, a ovoidal, uniform soft tissue attenuating and uniform moderate contrast enhancing mass is seen. The mass is extending caudally along the left cranial aspect of the heart. The cranioventral mediastinal mass is measuring 7.5 x 4.3 x 10.8 cm in size. The mass is in close contact with the cranial vena cava at the same level and the cranial costocervical vein is running through the mass. No intraluminal filling defects are appreciated in the cranial vena cava.

10 Years

The cardiovascular structures including the pulmonary vasculature are within normal limits.

INTERPRETED BY

Sebastian Schaub,
 DVM Dr. med. vet.
 DipECVDI

The bronchial tree presents with regular branching and tapers uniformly towards the periphery as expected, the bronchial walls are thin and smooth. The bronchus-to-artery ratio is within normal limits. The lung parenchyma presents the expected architecture and attenuation behavior with interspersed punctuate mineralization.

Small incidental gas pockets are seen within the esophageal lumen, there is no evidence of abnormal dilation.

HOSPITAL NAME

Mobile Pet Imaging

COMPUTED TOMOGRAPHIC DIAGNOSIS

- Cranioventral mediastinal soft tissue mass without evidence of vascular invasion
- Mild pleural effusion – likely paraneoplastic
- Pulmonary osteomas
- Spondylosis deformans
- Degenerative osteoarthritis shoulder joints bilaterally
- Congenital malformation transverse processes C7 – like rudimentary ribs
- No evidence of pulmonary metastatic disease

REFERRING VET

Dr. Meaux

INVOICE

33387

DATE

12/9/21

INTERPRETATION OF THE FINDINGS & FURTHER RECOMMENDATIONS

The cranioventral mediastinal mass is compatible with neoplasia and differentials include thymoma, thymic sarcoma/carcinoma, round cell tumor, less likely ectopic thyroid carcinoma, other. FNA sampling by the left first intercostal space – approximately in the ventral third – should be possible for blind FNA sampling. Ultrasound guided sampling is a safe and feasible method as well. Complete



PATIENT surgical excision of the mass appears feasible, although adhesion with the cranial vena cava might be present – the costocervical vein is embedded within the mass.

Eva Hemmer

SPECIES

Canine

BREED

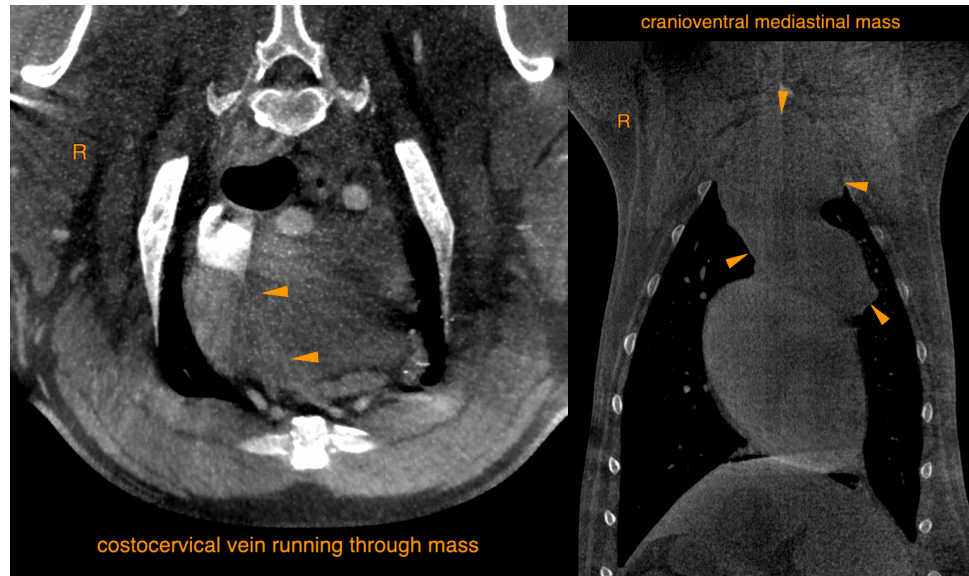
Rottweiler

SEX

Spayed Female

AGE

10 Years



INTERPRETED BY

Sebastian Schaub,
DVM Dr. med. vet.
DipECVDI

The information and recommendations provided are based on the images presented by the referring veterinarian. No evaluation can be communicated regarding pathology that was not visible in the image/video clips provided.

Thank you for this referral. If the clinical or image interpretation does not parallel your findings or if I can be of any further assistance please contact me.

HOSPITAL NAME

Mobile Pet Imaging

Sebastian Schaub, Sebastian Schaub, DVM, Dr. med. vet. DipECVDI
sebast.schaub@gmail.com

REFERRING VET

Dr. Meaux

INVOICE

33387

DATE

12/9/21