


**PATIENT PRESENTING CLINICAL SIGNS**

Mia Cassara Presented for COHAT, tooth root abscess repair of 108. Extracted 10 teeth, remaining are 104, 204, 405 and 406

**SPECIES COMPUTED TOMOGRAPHIC STUDY OF THE SKULL**

Canine A high resolution plain CT study of the skull is provided for review.

**COMPUTED TOMOGRAPHIC FINDINGS**
**BREED**

Teacup Poodle

The tooth elements 101-103, 105, 106, 109, 110, 201-203, 205-207, 209, 210, 301-303, 308, 310, 311, 401-403, 408, 410 and 411 are absent. Triadan 108, 208, 304, 306, 307, 309, 404, 405, 407 and 409 present a significant widening of the periodontal space. A small draining tract is seen at the mesial root of triadan 308. Generalized advanced horizontal bone loss in all jaw quadrants is seen. A moderate subcutaneous swelling is seen at the right aspect of the maxillary bone, level with triadan 107/108.

**SEX**

Spayed Female

The nasal cavity presents the expected aerated spaces between thin & even conchae and turbinates with smooth mucosal lining.

**AGE**

16 Years

Both temporomandibular joints present congruent joint spaces with even subchondral bone surfaces and are considered within normal limits.

Both tympanic bullae are aerated, the mucosal lining is not seen, the bony wall is smooth and thin. The external ear canals are within normal limits.

**INTERPRETED BY COMPUTED TOMOGRAPHIC DIAGNOSIS**

Sebastian Schaub,  
 DVM Dr. med. vet.  
 DipECVDI

- Generalized advanced periodontal disease, see above
- Suspect focal subcutaneous steatitis level 107/108
- Generalized significant horizontal bone loss in all jaw quadrants
- Multiple absent teeth, see above

**HOSPITAL NAME**

South Bay AH

**INTERPRETATION OF THE FINDINGS & FURTHER RECOMMENDATIONS**

There is evidence of generalized significant periodontal disease with tooth root abscess formation 108 & 208. A complete dental work up with extraction of the affected teeth has already been performed.

**REFERRING VET**

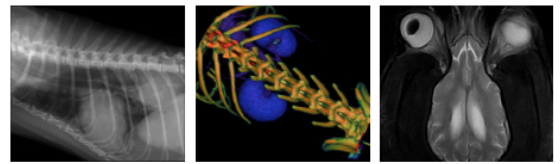
Dr. Rupashree Rao

**INVOICE**

33399

**DATE**

12/9/21



**PATIENT**

Mia Cassara

**SPECIES**

Canine

**BREED**

Teacup Poodle

**SEX**

Spayed Female

**AGE**

16 Years

**INTERPRETED BY**

Sebastian Schaub,  
DVM Dr. med. vet.  
DipECVDI

**HOSPITAL NAME**

South Bay AH

**REFERRING VET**

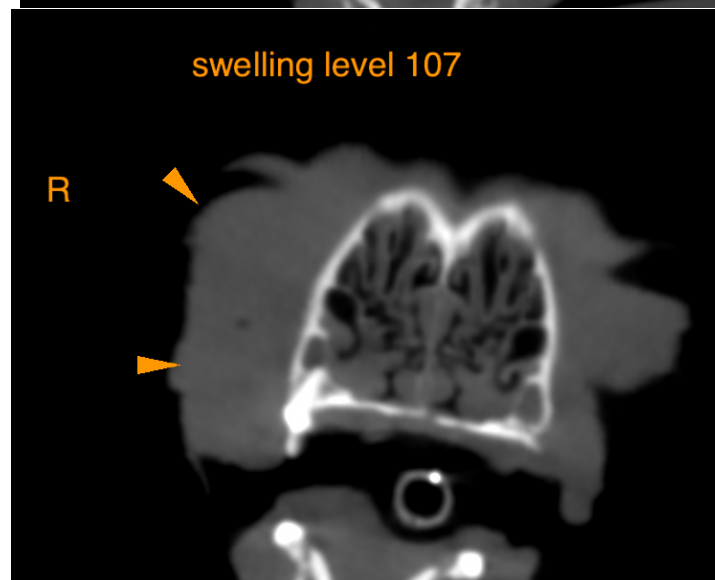
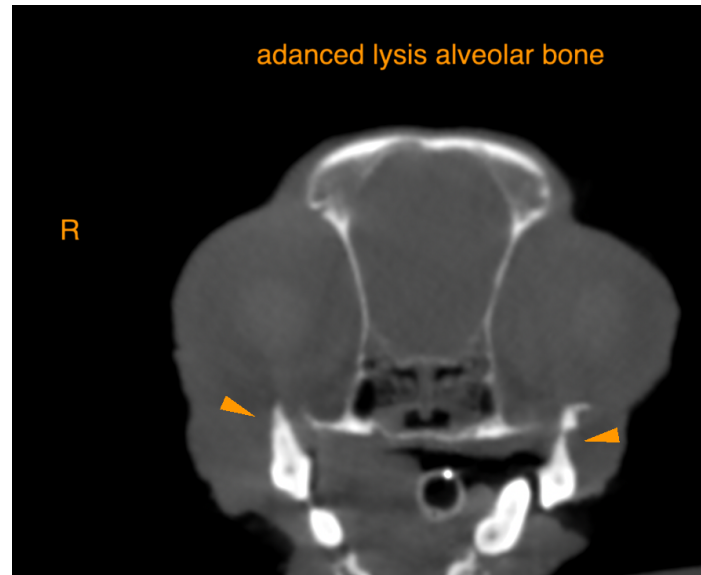
Dr. Rupashree Rao

**INVOICE**

33399

**DATE**

12/9/21



The information and recommendations provided are based on the images presented by the referring veterinarian. No evaluation can be communicated regarding pathology that was not visible in the image/video clips provided.

Thank you for this referral. If the clinical or image interpretation does not parallel your findings or if I can be of any further assistance please contact me.

Sebastian Schaub, Sebastian Schaub, DVM, Dr. med. vet. DipECVDI  
sebast.schaub@gmail.com