



PRESENTING CLINICAL SIGNS

PATIENT

Major Pritchett

History: Pet presented to clinic for right front leg lameness x 4 weeks. Prescribed gabapentin and Deramaxx about a week ago, with no improvement or worsening of symptoms. Pet seems stiff after getting up, but then will run around like there is no issue.

SPECIES

Canine

Abnormal PE/Chem/CBC/UA Results: Radiograph report from THORAX AND SKELETAL SURVEY, November 9, 2021: A single lateral radiograph of the thorax, a lateral radiograph of the right brachium, craniocaudal radiograph of both antebrachial extremities, ventrodorsal radiographs of the pelvis and medial lateral radiographs of the femur/crura are submitted. Total seven images.

BREED

Mixed

FINDINGS: There are no abnormalities of the trachea or major bronchi. The size and shape of the heart are within normal limits. The great vessels and pulmonary vessels are within normal limits. No pulmonary parenchymal abnormalities are present. The pleural cavity and mediastinum are unremarkable. The included abdominal viscera appear within normal limits. There are no significant changes of the extra thoracic structures. No abnormalities of the right shoulder are noted but assessment is compromised by superimposition of the cervical spine on the lateral projection. The right elbow and carpal joints appear normal. No changes are seen in the scapula, humerus, radius, ulna, metacarpals, or phalanges. There is no appreciable soft tissue swelling. The included craniocaudal radiograph of the left limb is unremarkable. The included abdominal viscera are normal and there is appropriate intra-abdominal serosal margin detail. The included spine is normal. The depth of the acetabula is adequate with good dorsal coverage of both femoral heads. There is normal congruency of both hips. No appreciable degenerative changes of the hips are noted. There are no other abnormalities of the pelvis or hips. The femurs are unremarkable. The stifle joints appear normal with no appreciable incongruency or degenerative change. The tarsal joints are normal in both limbs. No remodeling changes of the osseous structures are seen. No soft tissue swelling is noted.

SEX

Neutered Male

AGE

1 Year

CONCLUSIONS: 1. Unremarkable limited assessment of the thorax. 2. Unremarkable limited assessment of the right thoracic limb. 3. Unremarkable pelvis, femurs and GERD. COMMENTS: There is no overt lesion to account for the reported presenting signs. If response to therapy continues to be limited thoracic spine, consultation with a specialist orthopedic surgeon to review further diagnostic and therapeutic options could be considered. Repeat radiographs with improved positioning in 2 to 3 weeks could also be considered to reassess the osseous structures

INTERPRETED BY

Sebastian Schaub,
DVM Dr. med. vet.
DipECVDI

CONCLUSIONS: 1. Unremarkable limited assessment of the thorax. 2. Unremarkable limited assessment of the right thoracic limb. 3. Unremarkable pelvis, femurs and GERD. COMMENTS: There is no overt lesion to account for the reported presenting signs. If response to therapy continues to be limited thoracic spine, consultation with a specialist orthopedic surgeon to review further diagnostic and therapeutic options could be considered. Repeat radiographs with improved positioning in 2 to 3 weeks could also be considered to reassess the osseous structures

COMPUTED TOMOGRAPHIC STUDY OF THE SHOULDER JOINTS

HOSPITAL NAME

Advanced Animal
Imaging

A high resolution pre- and post-contrast CT study of the shoulder joints is provided for review.

COMPUTED TOMOGRAPHIC FINDINGS

REFERRING VET

Blair Hollowell, DVM

Electronic imaging labeling is flipped, AR is conserved as the left-sided of the patient and PL as the right - regarding the anatomy.

Both shoulder joints present smooth osseous margins and the surrounding soft tissue structures are within normal limits.

INVOICE

10024

The periarticular bones of the right elbow joint present mild osteophyte new bone formation. The right elbow joint presents a fissure line running in a mediolateral direction and demarcating and osseous segment measuring 4.2 x 4.2 x 5.1 mm in size.

DATE

12/9/21



PATIENT

Major Pritchett

COMPUTED TOMOGRAPHIC DIAGNOSIS

- Fragmented medial coronoid process (FCP) right elbow joint
- Mild degenerative osteoarthritis right elbow joint

SPECIES

Canine

- Normal shoulder joints bilaterally

INTERPRETATION OF THE FINDINGS & FURTHER RECOMMENDATIONS

BREED

Mixed

The findings are consistent with mild chronic degenerative joint disease of the right elbow joint due to a fragmented medial coronoid process.

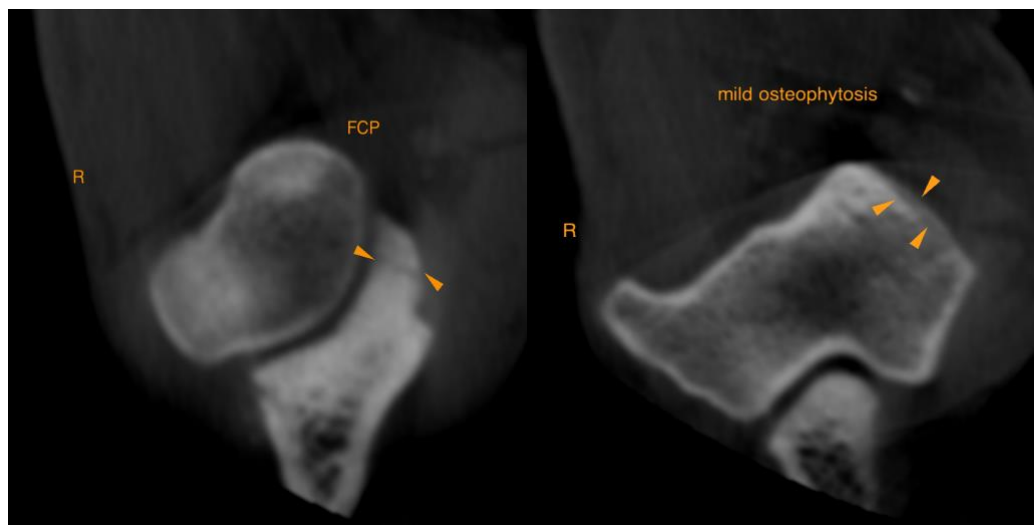
Arthroscopy is recommended to revise the elbow joint and remove the fragments of the medial coronoid process and prevent further damage.

SEX

Neutered Male

AGE

1 Year



INTERPRETED BY

Sebastian Schaub,
DVM Dr. med. vet.
DipECVDI

HOSPITAL NAME

Advanced Animal
Imaging

The information and recommendations provided are based on the images presented by the referring veterinarian. No evaluation can be communicated regarding pathology that was not visible in the image/video clips provided.

Thank you for this referral. If the clinical or image interpretation does not parallel your findings or if I can be of any further assistance please contact me.

REFERRING VET

Blair Hollowell, DVM

Sebastian Schaub, Sebastian Schaub, DVM, Dr. med. vet. DipECVDI
sebast.schaub@gmail.com

INVOICE

10024

DATE

12/9/21



PATIENT

Major Pritchett

SPECIES

Canine

BREED

Mixed

SEX

Neutered Male

AGE

1 Year

INTERPRETED BY

Sebastian Schaub,
DVM Dr. med. vet.
DipECVDI

HOSPITAL NAME

Advanced Animal
Imaging

REFERRING VET

Blair Hollowell, DVM

INVOICE

10024

DATE

12/9/21