



PATIENT

Lilly Dieckmann

PRESENTING CLINICAL SIGNS

P presented 24 hours following administration of FVRC/FeLV Combo vaccine on the distal right forelimb for swelling of the distal right forelimb and increased temperature. O has not noted any changes in dietary pattern, but P has been slightly more lethargic. O notes that inflammation has decreased, but is still present.

SPECIES

Feline

Abnormal PE/Chem/CBC/UA Results: - Gait III/IV changes on the right forelimb, intermittently non-weight-bearing. - Inflammation of the right forelimb antebrachium is 2-3 times that of the left antebrachium - Pain on palpation is decreased w/ administration of diphenhydramine and oral prednisolone syrup.

BREED

Siamese Mix

RADIOGRAPHIC STUDY OF THE FRONT LIMBS

Radiographs of the front limbs in two orthogonal imaging planes are provided for review.

SEX

Female

RADIOGRAPHIC FINDINGS

The growth plates are age related open.

AGE

10.9 Weeks

The right antebrachium presents with a significant circumferential homogeneous soft tissue swelling, extending from the level of the elbow joint distally up to the carpus. The osseous structures of the right front limb are within normal limits.

The osseous and soft tissue structures of the left front limb present without abnormalities.

INTERPRETED BY

Sebastian Schaub, DVM
Dr. med. vet. DipECVDI

RADIOGRAPHIC DIAGNOSIS

- Generalized soft tissue swelling right antebrachium

HOSPITAL NAME

Boca Park Animal Hospital

INTERPRETATION OF THE FINDINGS & FURTHER RECOMMENDATIONS

Given the history, inflammatory origin – infectious versus non-infectious – of the soft tissue swelling of the right antebrachium is likely. Complementing workup by an ultrasound examination would be beneficial to check for (subfascial) fluid pockets warranting surgical drainage.

REFERRING VET

Tifanie Silver

TECHNICAL COMMENTS

Human fingers/hands are seen in the primary beam, please consider radiation safety guidelines!

INVOICE

48970

DATE

12-9-21



PATIENT

Lilly Dieckmann

SPECIES

Feline

BREED

Siamese Mix

SEX

Female

AGE

10.9 Weeks

INTERPRETED BY

Sebastian Schaub, DVM
Dr. med. vet. DipECVDI

HOSPITAL NAME

Boca Park Animal
Hospital

REFERRING VET

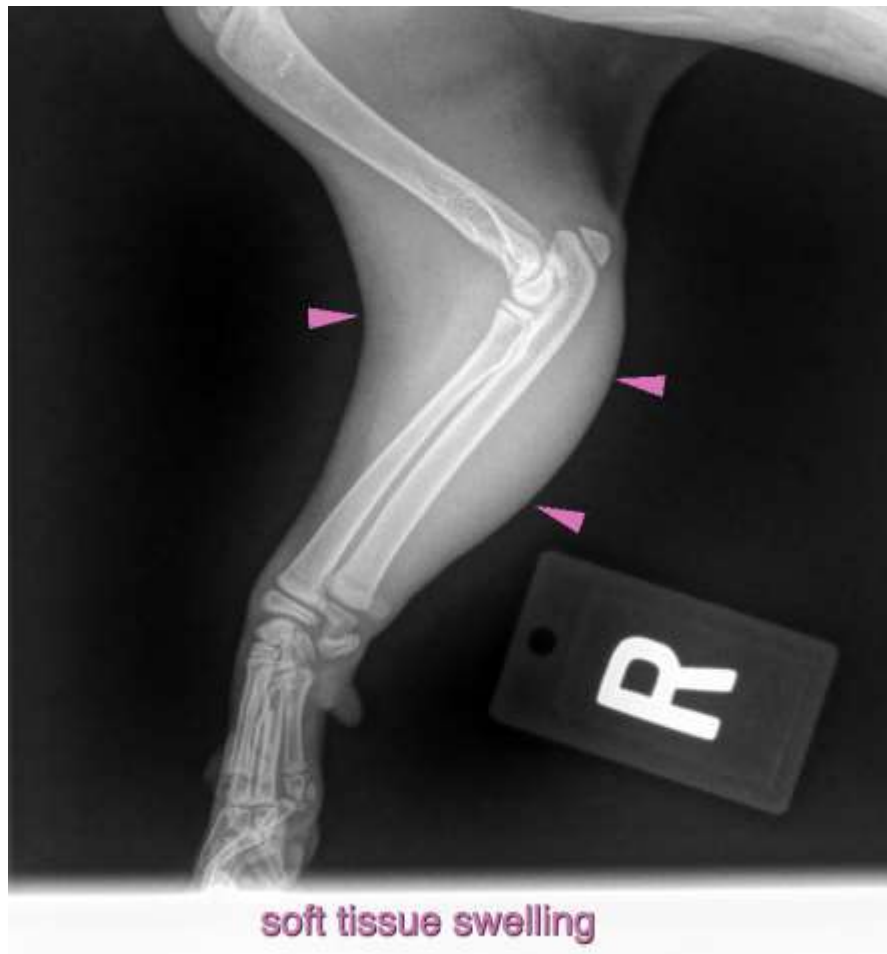
Tifanie Silver

INVOICE

48970

DATE

12-9-21



The information and recommendations provided are based on the images presented by the referring veterinarian. No evaluation can be communicated regarding pathology that was not visible in the image/video clips provided.

Thank you for this referral. If the clinical or image interpretation does not parallel your findings or if I can be of any further assistance please contact me.

Sebastian Schaub, Sebastian Schaub, DVM, Dr. med. vet. DipECVDI
sebast.schaub@gmail.com