



PATIENT

Evie Fox

SPECIES

Canine

BREED

French Bulldog

SEX

F

AGE

7Y, 11M

WEIGHT

16

INTERPRETED BY

Sebastian Schaub, DVM
Dr. med. vet.
DipECVDI

IMAGING PERFORMED BY

Patricia Sanchez
Sanchez

HOSPITAL NAME

Animal Trust - Bolton

REFERRING VET

Patricia Sanchez
Sanchez

INVOICE

72883

DATE

12-8-25

PRESENTING CLINICAL SIGNS

Lameness RFL since jumping from the sofa. Now swelling in the axillary area.
Abnormal PE/Chem/CBC/UA Results: NAD

COMPUTED TOMOGRAPHY OF THE FRONT LIMBS

A high resolution pre- and post-contrast CT study of the front limbs is provided for review.

COMPUTED TOMOGRAPHIC FINDINGS

In the right axillary region, an ill-defined, roundish, uniform soft tissue attenuating and heterogeneous contrast enhancing mass is seen; measuring approximately 10.0 x 8.5 x 10.0 cm. Abduction of the right front limb due to the mass effect is appreciated. The subcutaneous tissue of the right axillary region and right front limb presents a diffuse mild to moderate edematous swelling.

The periarticular bones of both shoulder joints are smooth, unremarkable.

No abnormalities of the osseous structures of both elbow joints are appreciated.

The surrounding soft tissue structures of the left front limb reveals no abnormalities.

COMPUTED TOMOGRAPHIC DIAGNOSIS

- Large ill-defined right axillary soft tissue mass without osseous involvement
- Generalized edematous swelling right front limb – paraneoplastic finding
- Normal shoulder joints
- Normal elbow joints

INTERPRETATION OF THE FINDINGS & FURTHER RECOMMENDATIONS

The right axillary soft tissue mass is consistent with primary soft tissue neoplasia – such as sarcoma or round cell tumor. The mass presents signs of invasive growth and if surgical management is considered – amputation of the right front limb along with scapulectomy would be warranted – and there is an increased risk for post operative local reoccurrence of the mass.



PATIENT

Evie Fox

SPECIES

Canine

BREED

French Bulldog

SEX

F

AGE

7Y, 11M

WEIGHT

16

INTERPRETED BY

Sebastian Schaub, DVM
Dr. med. vet.
DipECVDI

IMAGING PERFORMED BY

Patricia Sanchez
Sanchez

HOSPITAL NAME

Animal Trust - Bolton

REFERRING VET

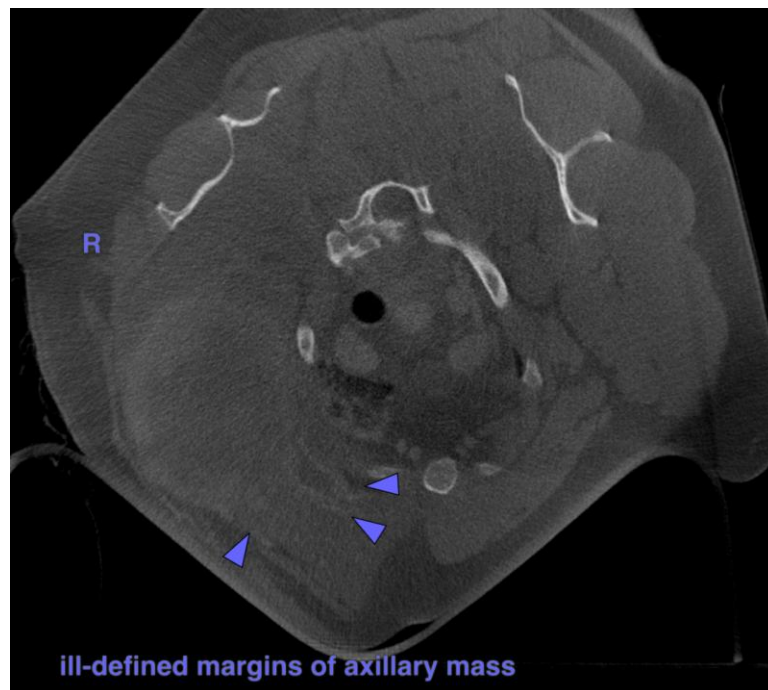
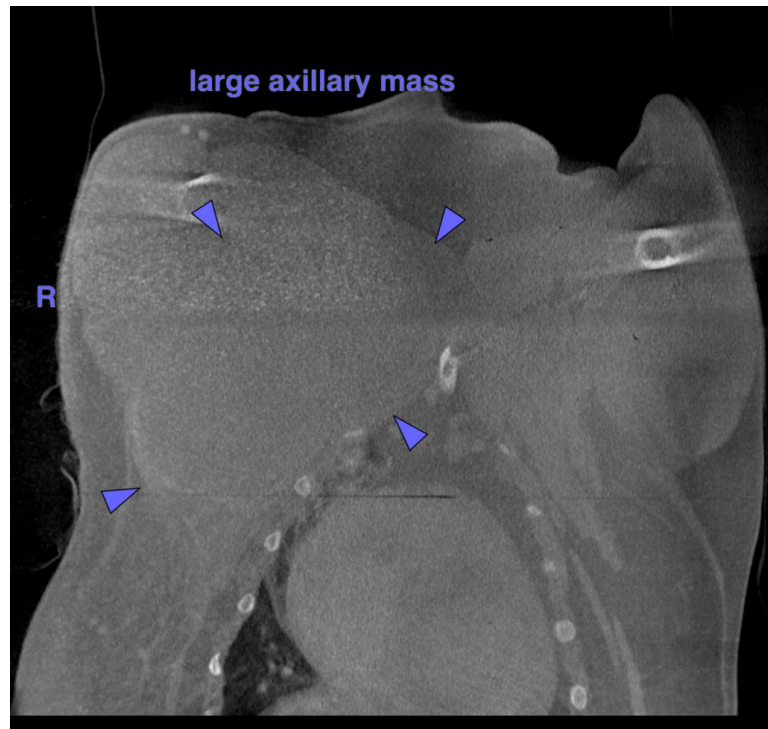
Patricia Sanchez
Sanchez

INVOICE

72883

DATE

12-8-25





PATIENT

Evie Fox

The information and recommendations provided are based on the images presented by the referring veterinarian/sonographer. No evaluation can be communicated regarding pathology that was not visible in the image/video clips provided.

SPECIES

Canine

Thank you for this referral. If the clinical or image interpretation does not parallel your findings or if I can be of any further assistance please contact me.

BREED

French Bulldog

Sebastian Schaub, Sebastian Schaub, DVM, Dr. med. vet. DipECVDI

info@sonopath.com

SEX

F

AGE

7Y, 11M

WEIGHT

16

INTERPRETED BY

Sebastian Schaub, DVM
Dr. med. vet.
DipECVDI

**IMAGING
PERFORMED BY**

Patricia Sanchez
Sanchez

HOSPITAL NAME

Animal Trust - Bolton

REFERRING VET

Patricia Sanchez
Sanchez

INVOICE

72883

DATE

12-8-25