



**PATIENT**

Heidi Cox

**PRESENTING CLINICAL SIGNS**

Chronic draining tract/crusting area below L eye - got better with abx therapy but never completely goes away - concern for FB or tooth root abscess

**SPECIES**

Canine

**COMPUTED TOMOGRAPHY OF THE SKULL**

A high resolution pre- and post-contrast CT study of the skull is provided for review.

**BREED**

Maltese

**COMPUTED TOMOGRAPHIC FINDINGS**

The tooth elements 105, 205 and 405 are absent Triadan 208 presents a marked periapical widening of the periodontal space of all tooth roots, perforating the cortex of the alveolar bone dorsally. The soft tissue at the lateral aspect of the maxillary bone level with triadan 208 is moderately swollen with multiple superficial gas inclusions. Marked periapical widening of the periodontal space of triadan 309 is seen, perforating the buccal cortex of the mandible at the same level. Triadan 409 shows a mild to moderate periapical widening of the periodontal space.

**SEX**

FS

The nasal cavity presents the expected aerated spaces between thin & even conchae and turbinates with smooth mucosal lining.

**AGE**

4

Both temporomandibular joints present congruent joint spaces with even subchondral bone surfaces and are considered within normal limits.

**INTERPRETED BY**

Sebastian Schaub, DVM  
Dr. med. vet. DipECVDI

Both tympanic bullae are aerated, the mucosal lining is not seen, the bony wall is smooth and thin. The external ear canals are within normal limits.

The brain presents no deviation from normal anatomy and symmetry. The brain parenchyma is homogeneous and within normal limits for attenuation and distribution of contrast enhancement. The ventricular system is non-dilated and symmetric.

**HOSPITAL NAME**

Advanced Animal  
Imaging

The left mandibular lymph nodes are prominent.

**COMPUTED TOMOGRAPHIC DIAGNOSIS**

**REFERRING VET**

Blair Hollowell, DVM

- Periapical abscess formation triadan 208, 309 and 409
- Focal subcutaneous septic steatitis with draining tract level with triadan 208
- Reactive hyperplasia left mandibular lymph nodes
- Absent triadan 105, 205 and 405

**INTERPRETATION OF THE FINDINGS & FURTHER RECOMMENDATIONS**

**INVOICE**

48906

The findings are compatible with dental abscess formation triadan 208 with secondary steatitis and draining tract – explaining the clinical signs. Recommend a complete dental workup, with extraction of the affected teeth.

**DATE**

12-8-21



**PATIENT**

Heidi Cox

**SPECIES**

Canine

**BREED**

Maltese

**SEX**

FS

**AGE**

4

**INTERPRETED BY**

Sebastian Schaub, DVM  
Dr. med. vet. DipECVDI

**HOSPITAL NAME**

Advanced Animal  
Imaging

**REFERRING VET**

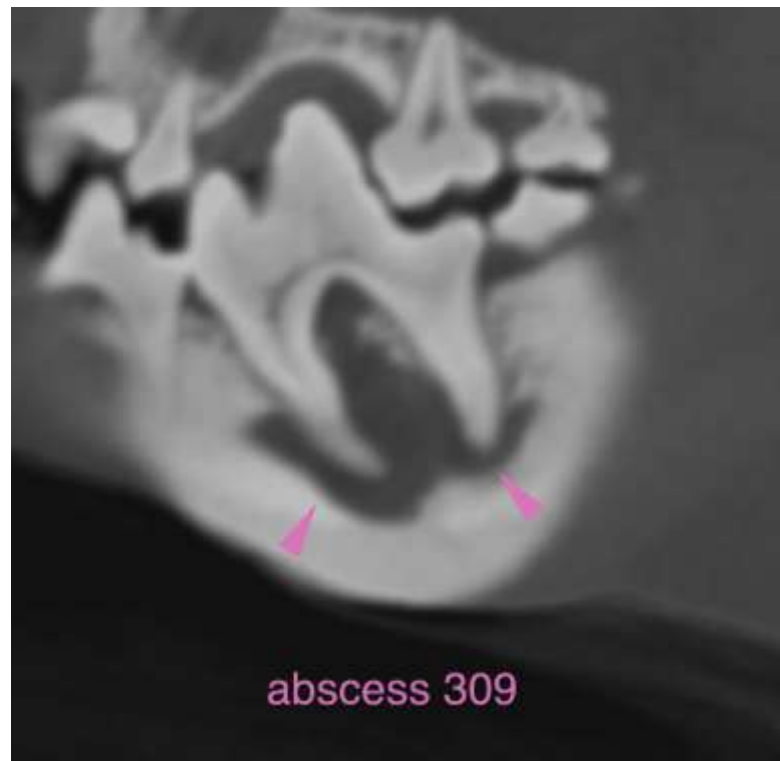
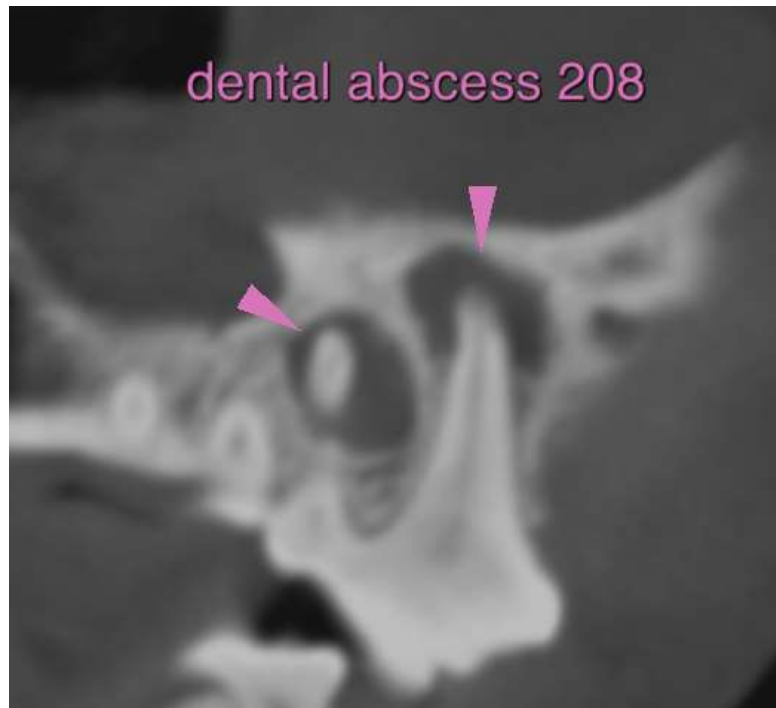
Blair Hollowell, DVM

**INVOICE**

48906

**DATE**

12-8-21





**PATIENT**

Heidi Cox

**SPECIES**

Canine

**BREED**

Maltese

**SEX**

FS

**AGE**

4

**INTERPRETED BY**

Sebastian Schaub, DVM  
Dr. med. vet. DipECVDI

**HOSPITAL NAME**

Advanced Animal  
Imaging

**REFERRING VET**

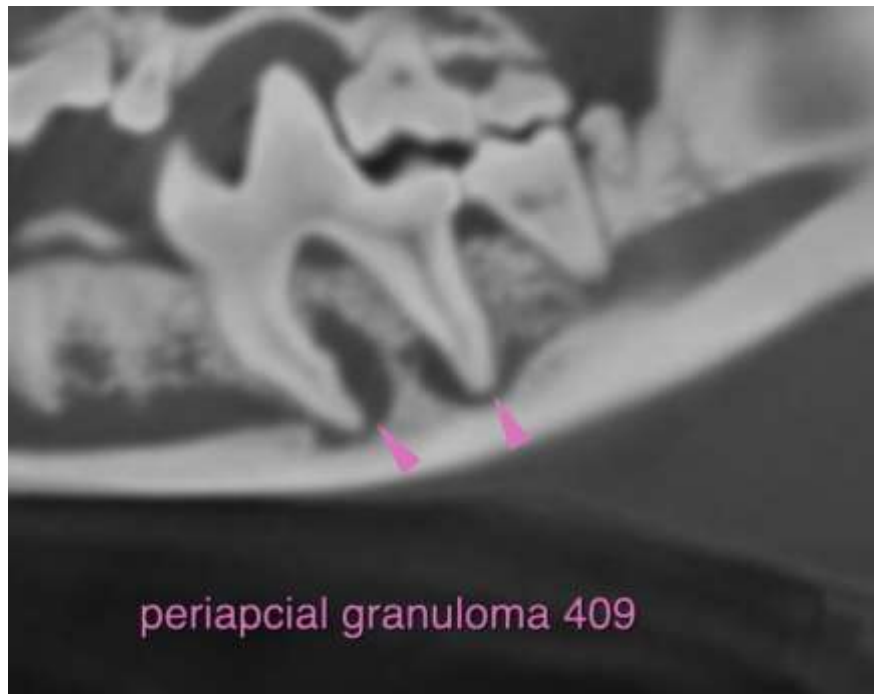
Blair Hollowell, DVM

**INVOICE**

48906

**DATE**

12-8-21



The information and recommendations provided are based on the images presented by the referring veterinarian. No evaluation can be communicated regarding pathology that was not visible in the image/video clips provided.

Thank you for this referral. If the clinical or image interpretation does not parallel your findings or if I can be of any further assistance please contact me.

**Sebastian Schaub**, Sebastian Schaub, DVM, Dr. med. vet. DipECVDI  
sebast.schaub@gmail.com