

**PATIENT**

Doug Kleinberg

**PRESENTING CLINICAL SIGNS**

prominence of right rib #13 compared to left Dr Molinelli feels normal variant but owner wants to confirm  
Abnormal PE/Chem/CBC/UA Results:

**SPECIES**

Canine

**RADIOGRAPHIC STUDY OF THE THORAX**

Radiographs of the thorax in two imaging planes are provided for review.

**BREED**

Golden Doodle

**RADIOGRAPHIC FINDINGS**

The 13<sup>th</sup> right rib presents a increased width and is fused to the vertebral body of T13.

The extrathoracic soft tissues present homogeneous without abnormalities.

**SEX**

Male Neutered

The heart is of normal size and shape, there is no evidence of cardiac chamber or vascular enlargement. The pulmonary vasculature is within normal limits.

The cranial mediastinum presents the expected soft tissue opacity. The mediastinal width is less than twice the width of the vertebral column at the same level.

**AGE**

3 Years, 9 Months

The trachea is normal in diameter and presents the anticipated course. The luminal outline of the trachea is smooth.

**INTERPRETED BY**

Sebastian Schaub, DVM  
Dr. med. vet. DipECVDI

The bronchial tree presents with thin walls and tapers uniformly towards the periphery as expected.

The lung parenchyma presents the expected architecture and opacity; the intrapulmonary vascular branching is seen up to the third order lung vessels.

**HOSPITAL NAME**

Belvedere Veterinary  
Center

The diaphragm is well delineated with even surface and the expected mild cranial bulging of the diaphragmatic cupola.

**RADIOGRAPHIC DIAGNOSIS****REFERRING VET**

Dr. Jamie Molinelli

- Normal anatomical variant of the 13<sup>th</sup> right rib, presenting an increased width and is fused to the vertebral body of T13

**INTERPRETATION OF THE FINDINGS & FURTHER RECOMMENDATIONS****INVOICE**

48862

The radiographic study of the thorax presents without abnormalities, the abnormal shape of the 13<sup>th</sup> right rib is a normal anatomical variant.

**DATE**

12-7-21



**PATIENT**

Doug Kleinberg

**SPECIES**

Canine

**BREED**

Golden Doodle

**SEX**

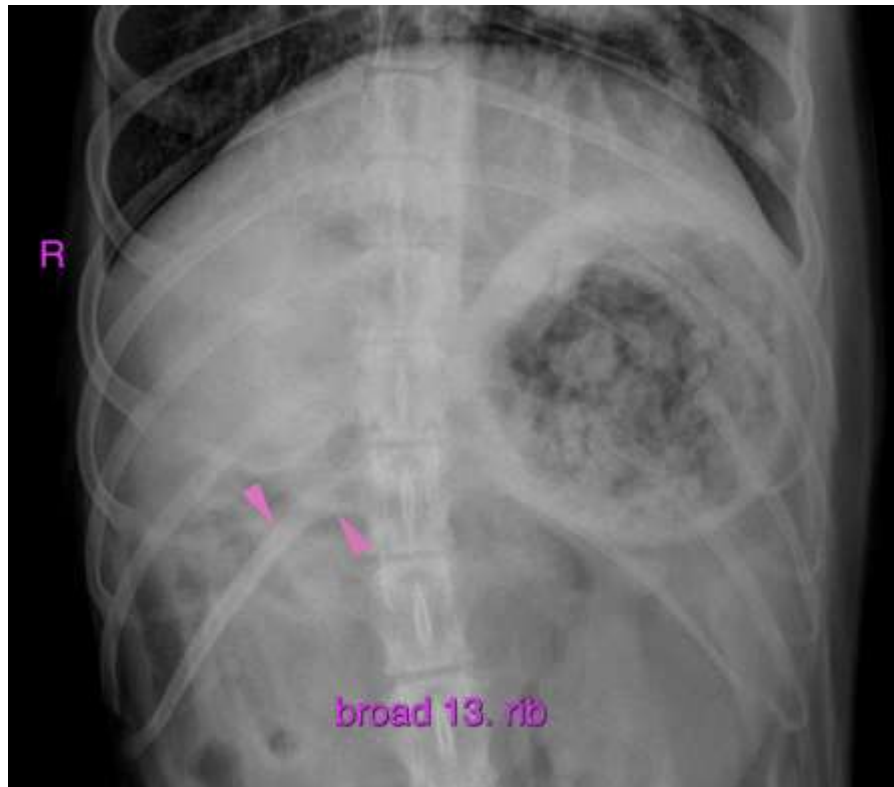
Male Neutered

**AGE**

3 Years, 9 Months

**INTERPRETED BY**

Sebastian Schaub, DVM  
Dr. med. vet. DipECVDI



**HOSPITAL NAME**

Belvedere Veterinary  
Center

**REFERRING VET**

Dr. Jamie Molinelli

**INVOICE**

48862

**DATE**

12-7-21

The information and recommendations provided are based on the images presented by the referring veterinarian. No evaluation can be communicated regarding pathology that was not visible in the image/video clips provided.

Thank you for this referral. If the clinical or image interpretation does not parallel your findings or if I can be of any further assistance please contact me.

**Sebastian Schaub**, Sebastian Schaub, DVM, Dr. med. vet. DipECVDI  
sebast.schaub@gmail.com