



PATIENT PRESENTING CLINICAL SIGNS

Gunner Kappel History: 2 weeks of neck/back pain. Has been on Metacam/gabapentin and methocarbamol , He is still acting painful at home, has been rested for 2 weeks but still not his normal self

SPECIES RADIOGRAPHIC STUDY OF THE NECK

Canine Radiographs of the neck in two orthogonal imaging planes are provided for review.

BREED RADIOGRAPHIC FINDINGS

Basset Hound Irregular mineral opaque material is seen in the imaging plane of the intervertebral disc space C5/C6; the respective neuroforamen has a subjective increased radiopacity. The intervertebral disc spaces along the cervical spine present an even width.

SEX The remainder of the osseous and soft tissue structures of the neck present without abnormalities.

Neutered Male

RADIOGRAPHIC DIAGNOSIS

- Chondroid disc degeneration C5/C6

AGE 10 Years

INTERPRETATION OF THE FINDINGS & FURTHER RECOMMENDATIONS

The increased radiopacity of the neuroforamen C5/C6 can be a sequela to superimposition with the scapulae or present extruded mineralized disc material. Depending on the development of clinical signs under empirical therapy, cross-sectional imaging can be used to confirm diagnosis of compressive myelopathy and decision making if surgical decompression is a consideration here.

INTERPRETED BY

Sebastian Schaub,
DVM Dr. med. vet.
DipECVDI

HOSPITAL NAME

Sylvan Lake VC

REFERRING VET

Dr. Andrew Hodges

INVOICE

19046

DATE

12/6/22



PATIENT

Gunner Kappel

SPECIES

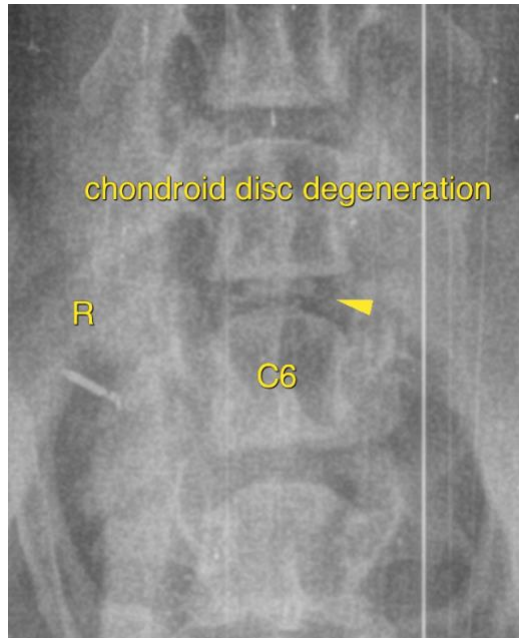
Canine

BREED

Basset Hound

SEX

Neutered Male



AGE

10 Years

The information and recommendations provided are based on the images presented by the referring veterinarian/sonographer. No evaluation can be communicated regarding pathology that was not visible in the image/video clips provided.

INTERPRETED BY

Sebastian Schaub,
DVM Dr. med. vet.
DipECVDI

Thank you for this referral. If the clinical or image interpretation does not parallel your findings or if I can be of any further assistance please contact me.

Sebastian Schaub, Sebastian Schaub, DVM, Dr. med. vet. DipECVDI
sebast.schaub@gmail.com

HOSPITAL NAME

Sylvan Lake VC

REFERRING VET

Dr. Andrew Hodges

INVOICE

19046

DATE

12/6/22