

**PATIENT**

Roxy Oppelt

PRESENTING CLINICAL SIGNS

HIND END WEAKNESS , CRANIAL DRAWER PRESENT

SPECIES

Canine

COMPUTED TOMOGRAPHY OF THE HIND LIMBS

A high resolution pre- and post-contrast CT study of the hind limbs is provided for review.

BREED

Maltese Mix

The body condition score is 9/9.

The coxofemoral joints present smooth osseous margins, unremarkable.

SEX

Spayed Female

The periarticular bones of the right stifle joint present moderate to marked osteophyte new bone formation. The right stifle joint presents a moderate intracapsular soft tissue swelling and mild thickening of the joint capsule is appreciated.

The periarticular bones of the left stifle joint show mild osteophyte new bone formation.

AGE

4

No abnormalities of the distal aspects of the hind limbs are noted.

INTERPRETED BYSebastian Schaub, DVM
Dr. med. vet. DipECVDI

- Obesity
- Advanced degenerative osteoarthritis right stifle joint
- Joint effusion & synovialitis right stifle joint
- Mild degenerative osteoarthritis left stifle joint

HOSPITAL NAMEAloha Pet & Bird
Hospital**INTERPRETATION OF THE FINDINGS & FURTHER RECOMMENDATIONS**

The CT study is consistent with advanced chronic degenerative osteoarthritis with concomitant joint effusion of the right stifle joint. The left stifle joint presents evidence of mild degenerative joint disease. The most-likely underlying cause is (partial) rupture of the cranial cruciate ligament with or without meniscal disease.

REFERRING VET

Dr. J. Pepen

A positive drawer sign has already been appreciated, supporting the diagnosis and surgical intervention appears beneficial. Consider treatment of accompanying comorbidities such as the obesity and rule out accompanying myelopathy (e.g. IVD protrusion/extrusion) as well.

INVOICE

48824

DATE

12-6-21



PATIENT

Roxy Oppelt

SPECIES

Canine

BREED

Maltese Mix

SEX

Spayed Female

AGE

4

INTERPRETED BY

Sebastian Schaub, DVM
Dr. med. vet. DipECVDI

HOSPITAL NAME

Aloha Pet & Bird
Hospital

REFERRING VET

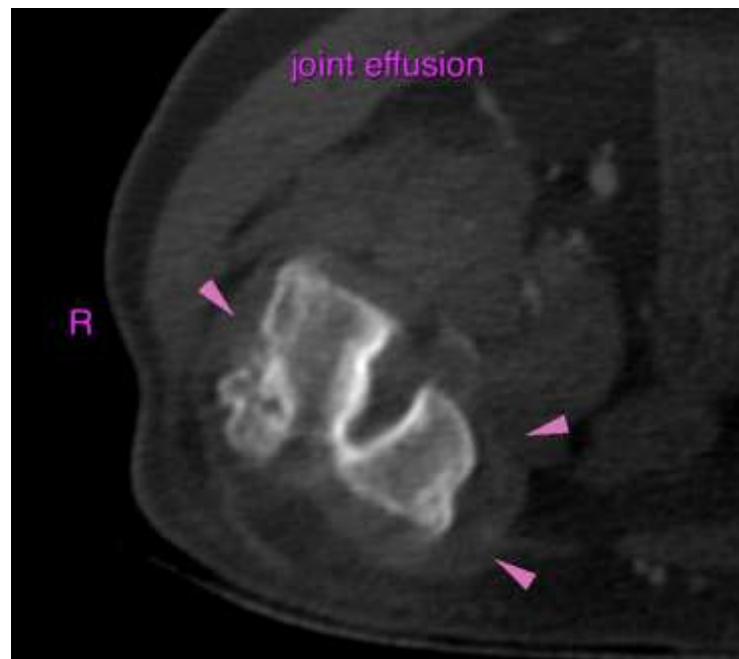
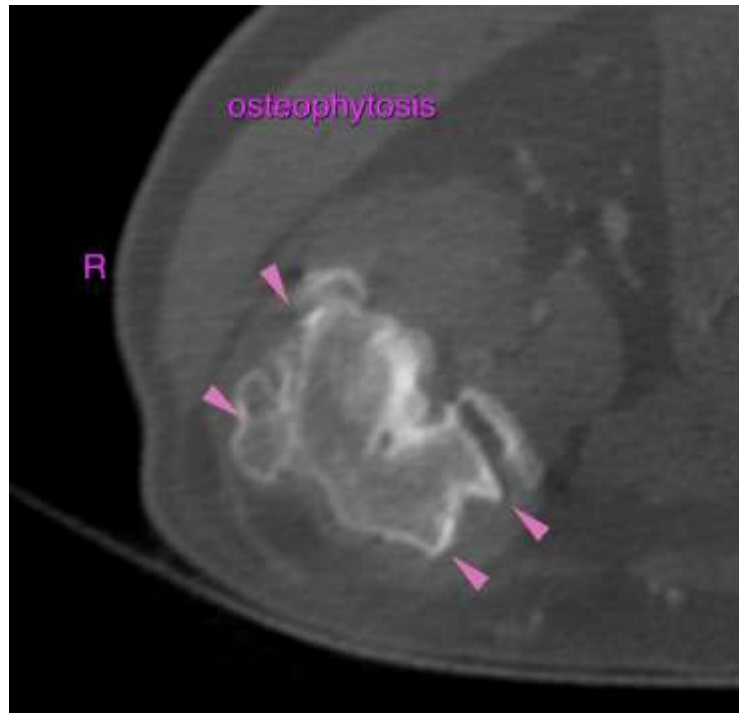
Dr. J. Pepen

INVOICE

48824

DATE

12-6-21





PATIENT

Roxy Oppelt

SPECIES

Canine

BREED

Maltese Mix

SEX

Spayed Female

AGE

4

INTERPRETED BY

Sebastian Schaub, DVM
Dr. med. vet. DipECVDI

HOSPITAL NAME

Aloha Pet & Bird
Hospital

REFERRING VET

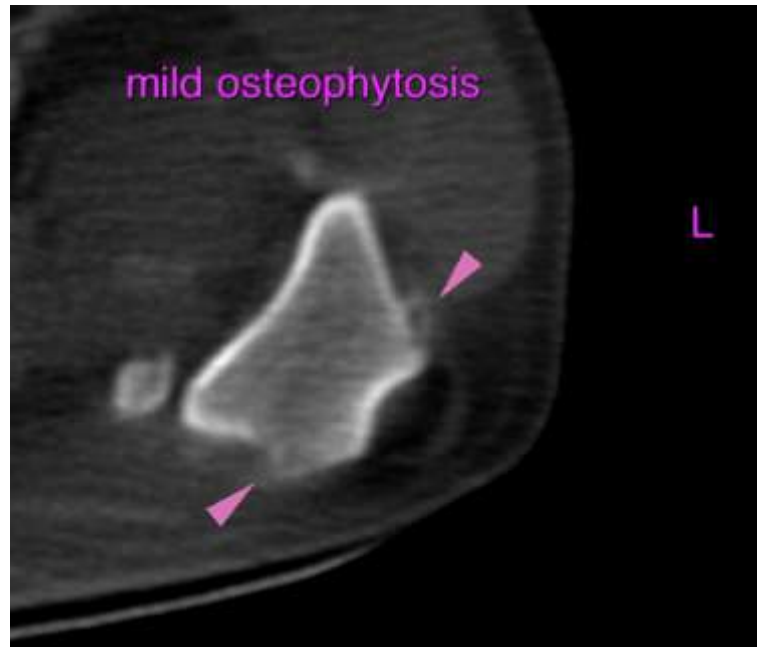
Dr. J. Pepen

INVOICE

48824

DATE

12-6-21



The information and recommendations provided are based on the images presented by the referring veterinarian. No evaluation can be communicated regarding pathology that was not visible in the image/video clips provided.

Thank you for this referral. If the clinical or image interpretation does not parallel your findings or if I can be of any further assistance please contact me.

Sebastian Schaub, Sebastian Schaub, DVM, Dr. med. vet. DipECVDI
sebast.schaub@gmail.com