



**PATIENT PRESENTING CLINICAL SIGNS**

Pranky Krystjaniak History: Sudden onset lameness LH since 1.12.22, non wt bearing, L popliteal LN enlarged, slight laxity in cruciate, swelling in quadriceps. Reluctant to extend hip, ok on flexion. No obvious bony issues radiographically on 4.12.22. On exam today L hip painful on extension and flexion

**SPECIES COMPUTED TOMOGRAPHIC STUDY OF THE PELVIS**

Canine A high resolution pre- and post-contrast CT study of the pelvis is provided for review.

**BREED COMPUTED TOMOGRAPHIC FINDINGS**

JRT The osseous and surrounding soft tissue structures of the pelvis are within normal limits. Both coxofemoral joints present smooth osseous margins and congruent joint spaces. Post contrast administration, no pathological distribution of the contrast media is appreciated.

**SEX COMPUTED TOMOGRAPHIC DIAGNOSIS**

Male

- Normal pelvis & coxofemoral joints

**AGE INTERPRETATION OF THE FINDINGS & FURTHER RECOMMENDATIONS**

9 Months The current CT study of the pelvis/coxofemoral joints presents without abnormalities of the osseous and soft tissue structures. There is no evidence of pathological effusion of the coxofemoral joints or inflammatory soft tissue lesions. Rule out pathology of the distal aspects of the hind limbs as cause for the lameness as well.

**INTERPRETED BY**

Sebastian Schaub,  
DVM Dr. med. vet.  
DipECVDI

**HOSPITAL NAME**

Myerscough VG

**REFERRING VET**

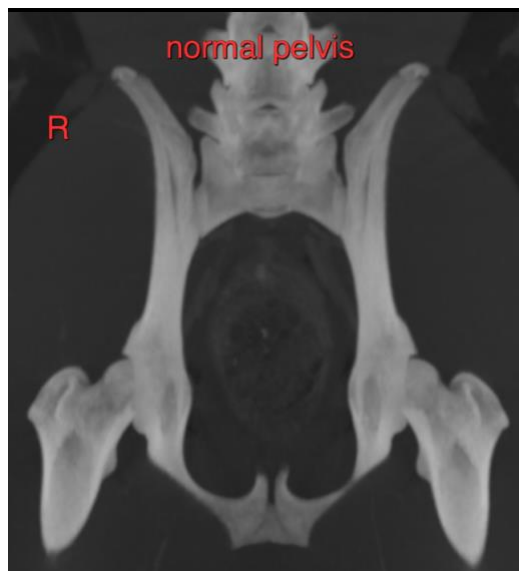
Dr. Orlin Angelov

**INVOICE**

18998

**DATE**

12/5/22





**PATIENT** The information and recommendations provided are based on the images presented by the referring veterinarian/sonographer. No evaluation can be communicated regarding pathology that was not visible in the image/video clips provided.

Pranky Krystjaniak

**SPECIES** Thank you for this referral. If the clinical or image interpretation does not parallel your findings or if I can be of any further assistance please contact me.

Canine

**Sebastian Schaub**, Sebastian Schaub, DVM, Dr. med. vet. DipECVDI  
sebast.schaub@gmail.com

**BREED**

JRT

**SEX**

Male

**AGE**

9 Months

**INTERPRETED BY**

Sebastian Schaub,  
DVM Dr. med. vet.  
DipECVDI

**HOSPITAL NAME**

Myerscough VG

**REFERRING VET**

Dr. Orlin Angelov

**INVOICE**

18998

**DATE**

12/5/22