



**PATIENT PRESENTING CLINICAL SIGNS**

Beau Passfield History: Limping , not fully bearing weight on front left shoulder

**RADIOGRAPHIC STUDY OF THE SHOULDER JOINTS**

**SPECIES**

Canine Radiographs of both shoulder joints in two imaging planes are provided for review. Radiographs are provided in JPEG file format.

**RADIOGRAPHIC FINDINGS**

**BREED**

Boxer There is moderate image noise due to underexposure.

**SEX**

In the mediolateral projection, the right shoulder joint is superimposed on the cranial segment of the sternum. The proximal metaphysis of the left shoulder joint presents a mild heterogeneous pattern of the medullary cavity.

Neutered Male

The radiographs of the right shoulder joint present without overt abnormalities, but moderate image noise.

**AGE**

**RADIOGRAPHIC DIAGNOSIS**

11 Years

- Heterogeneous pattern left proximal humerus

**INTERPRETATION OF THE FINDINGS & FURTHER RECOMMENDATIONS**

**INTERPRETED BY**

Sebastian Schaub,  
DVM Dr. med. vet.  
DipECVDI

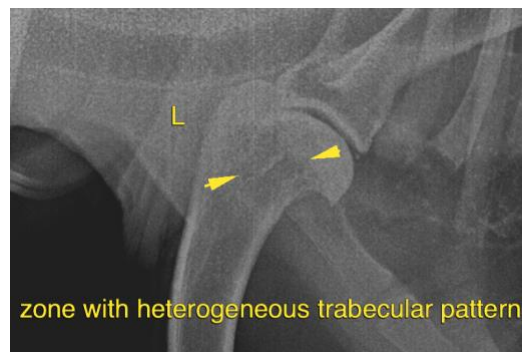
The heterogeneity of the proximal metaphysis of the left humerus can be the result of superimposition with the sternum in combination with image noise. However, an aggressive bone lesion cannot be ruled out – such as osteosarcoma. Recommend repeating the radiographs of the shoulder joints with the shoulder joint pulled cranioventrally to avoid superimposition and primary beam centered on the shoulder joint.

**HOSPITAL NAME**

Dr. Sam

**REFERRING VET**

Dr. Yessa



**INVOICE**

zone with heterogeneous trabecular pattern

19026

**DATE**

12/5/22



**PATIENT** The information and recommendations provided are based on the images presented by the referring veterinarian/sonographer. No evaluation can be communicated regarding pathology that was not visible in the image/video clips provided.

Beau Passfield

Thank you for this referral. If the clinical or image interpretation does not parallel your findings or if I can be of any further assistance please contact me.

**SPECIES**

Canine

**Sebastian Schaub**, Sebastian Schaub, DVM, Dr. med. vet. DipECVDI  
sebast.schaub@gmail.com

**BREED**

Boxer

**SEX**

Neutered Male

**AGE**

11 Years

**INTERPRETED BY**

Sebastian Schaub,  
DVM Dr. med. vet.  
DipECVDI

**HOSPITAL NAME**

Dr. Sam

**REFERRING VET**

Dr. Yessa

**INVOICE**

19026

**DATE**

12/5/22